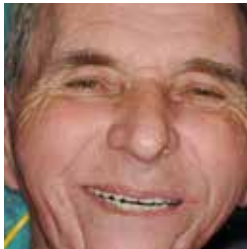



Clinical
casebook

Hybrid
Prosthetics

Impressions



List of cases

Case 1:

Brigitte Wascher, DT, and Dr Andreas Schaller

Austria

6

Case 2:

Daniele Rimoli, DT, PD Dr med. dent. Stephan Studer
and **Dr Dr med. dent. Marius Bredell**, Switzerland

10

Case 3:

Yves Gastard, DT, and Dr Guillaume Lance

France

14

Case 4:

Jean-Yves Ciers, DT, and Dr Philippe Gerentes

France

18

Case 5:

Dr Enrico Agliardi

Italy

22

Case 6:

Dr Nicolae Iuga and Christian Petri, DT

Romania

26

Case 7:

Pasquale Lacasella, DT, and Dr Pietro Venezia

Italy

30

Hygiene notes:

Dr Frank Zimmerling

Liechtenstein

34

In all the cases shown, SR Phonares® II denture teeth and IvoBase® denture base material were used. The denture base and the denture teeth were characterized with the laboratory composite SR Nexco®.

For a lasting smile

Many patients wish to regain a carefree smile. In these cases, removable dentures offer innovative solutions. Irrespective of the starting situation, fully coordinated products help to produce esthetic and functional high-quality results. The ultimate goal is not only to restore the patients' smile, but also their self-confidence.

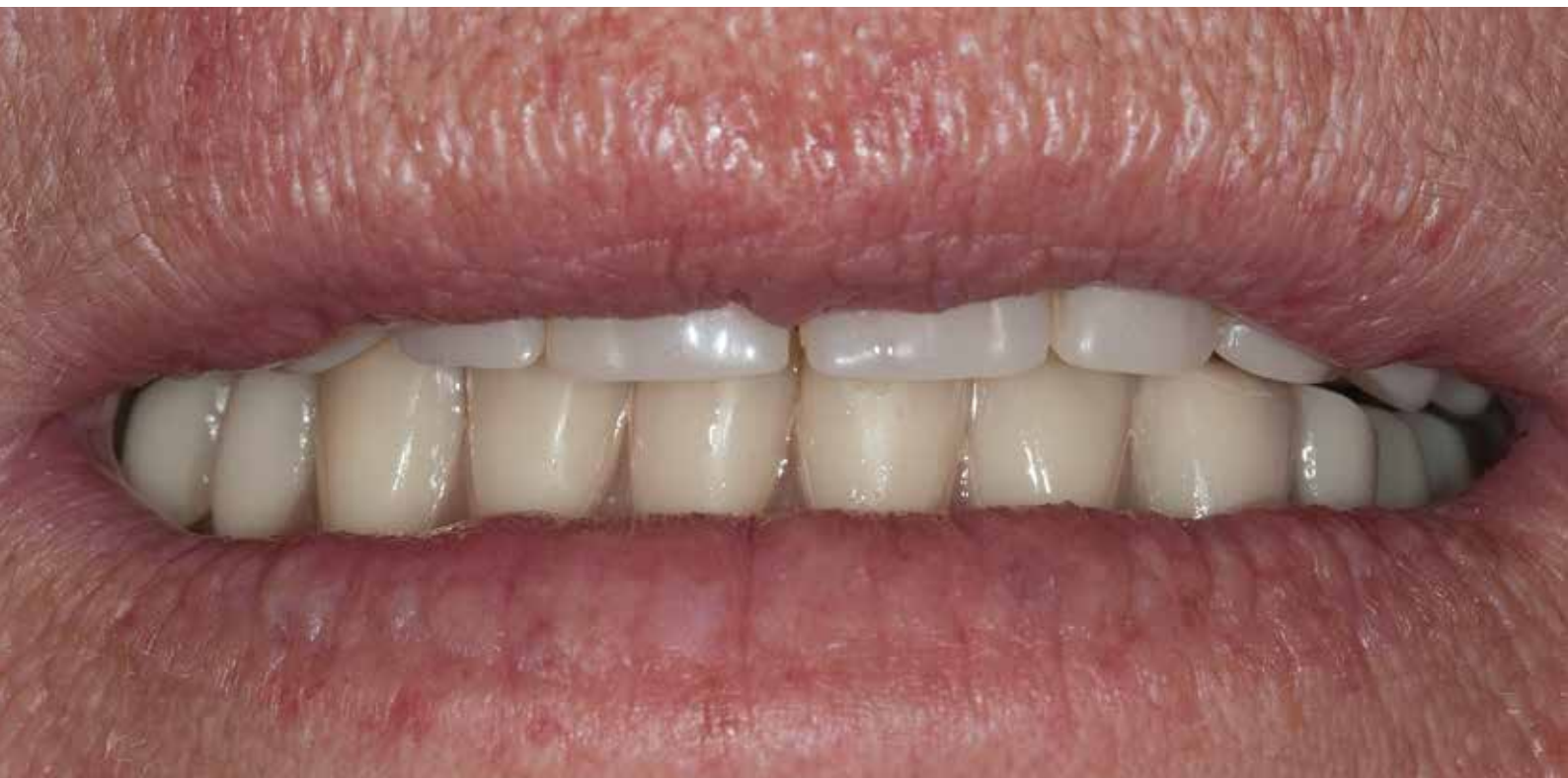

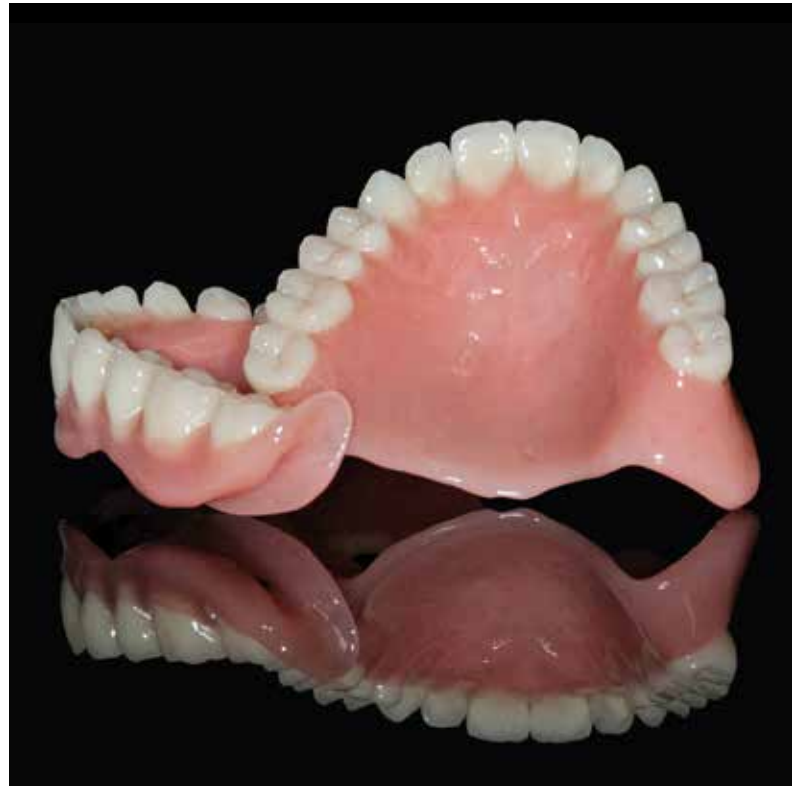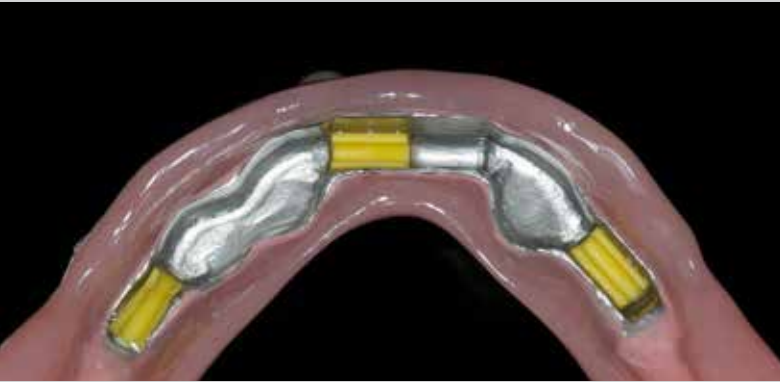
Brigitte Wascher, DT
PC-Dental GmbH & CoOG
Landskron, Austria

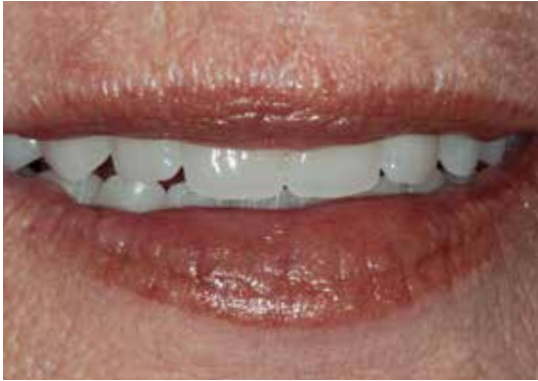

Dr. Andreas Schaller
Feistritz/Drau, Austria

"The main aim of dental lab technology and all its different disciplines is to copy nature. Passion and teamwork paired with the appropriate system and exclusive materials enable us to achieve results that come quite close to the natural example: Back to nature."









Daniele Rimoli, DT
Labor Baumgartner & Studer
Zurich, Switzerland

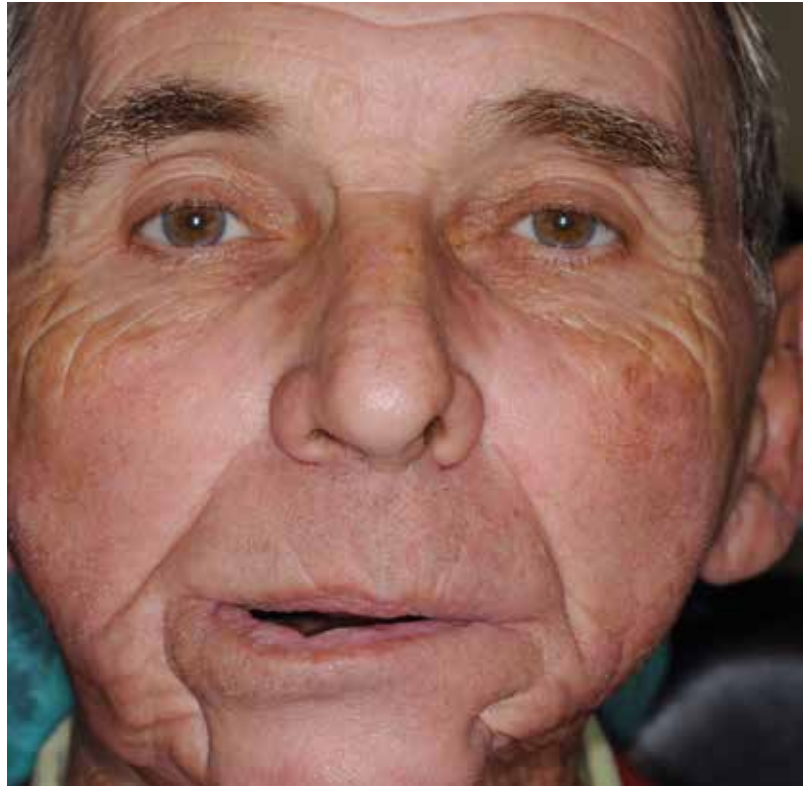

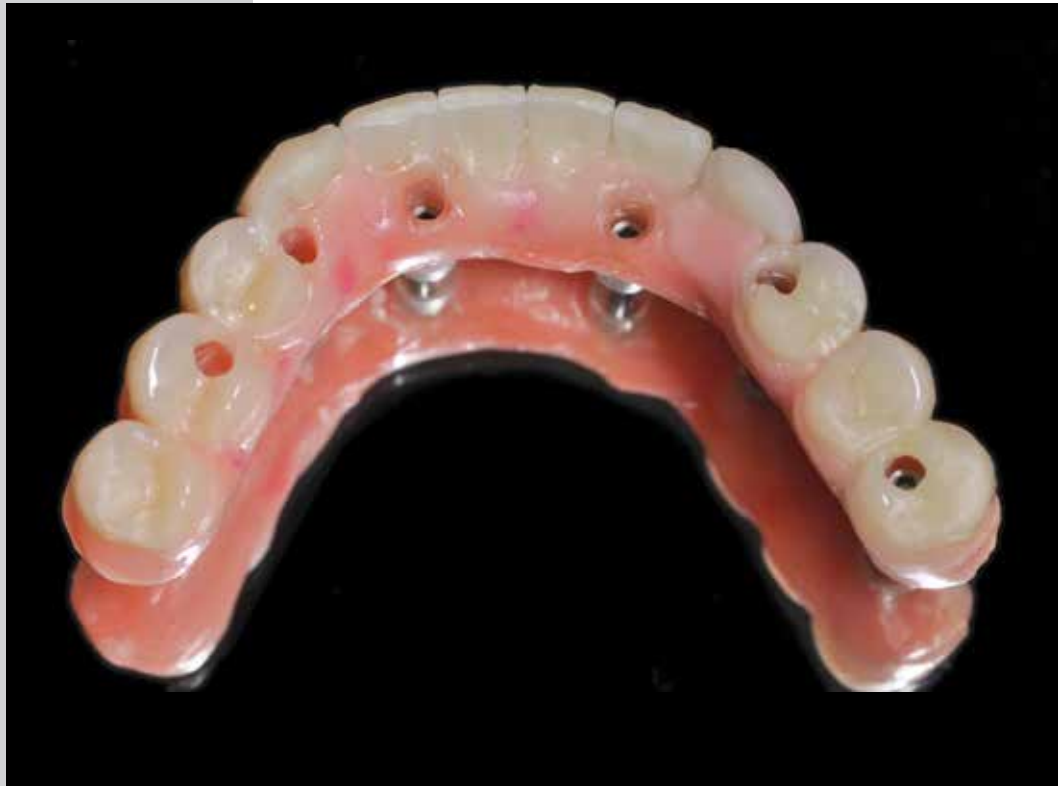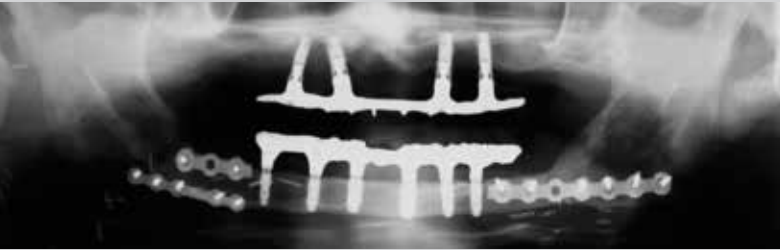
**PD Dr med. dent.
Stephan Studer**
Zahnmedizinische Praxis für
Tumorprothetik
Zurich, Switzerland

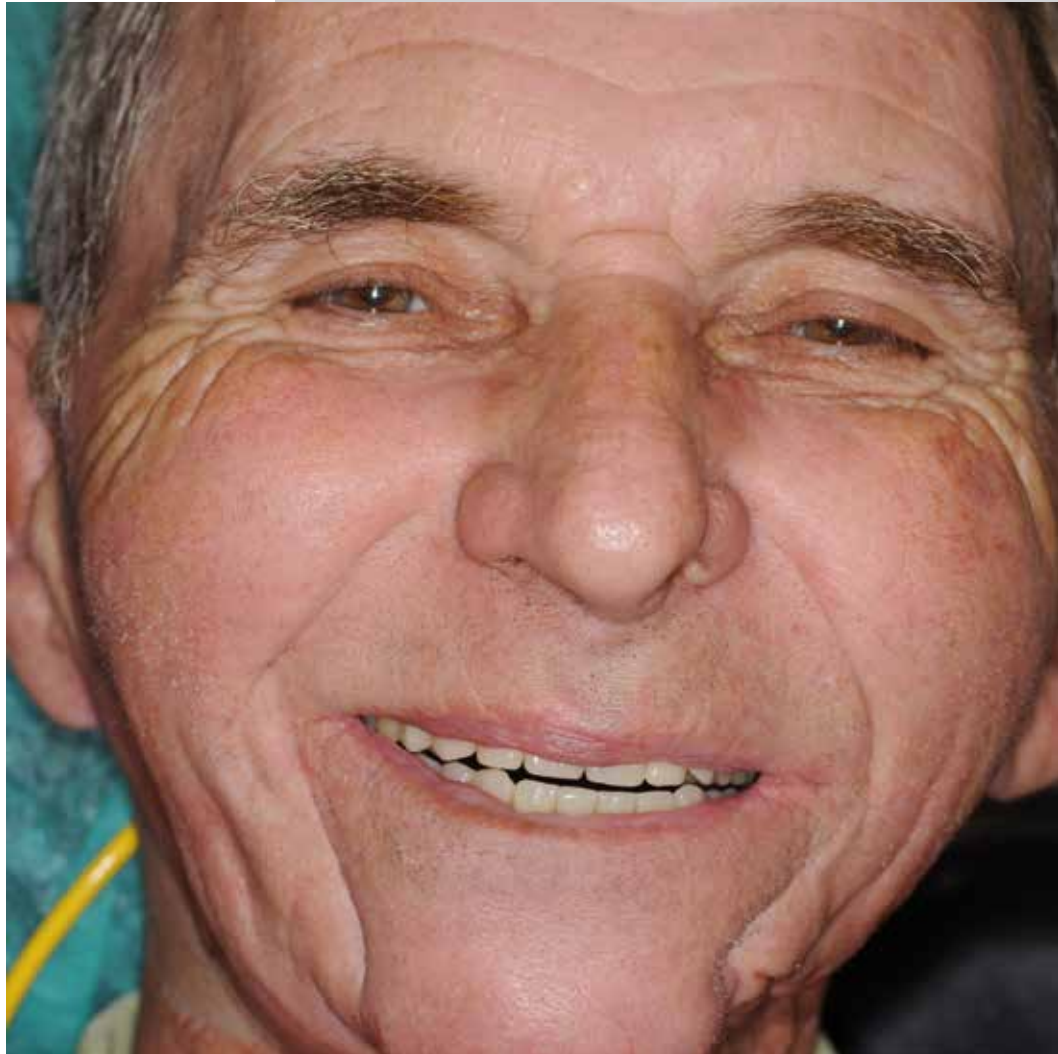


**Dr Dr med. dent.
Marius Bredell**
Dept. of Cranio-Maxillo-
Facial Surgery
University Hospital of Zurich,
Switzerland

"The interdisciplinary treatment of a tumour patient presented a considerable challenge. This case illustrates the treatment of mandibular osteoradionecrosis after "old-fashioned" radiotherapy. As a consequence, the patient lost part of the lower jawbone. It was surgically reconstructed with the help of vascularized fibula grafting. Subsequently, the patient received six implants. A screw-retained implant bridge and suitable denture teeth were used to restore the appearance of the lower lip."







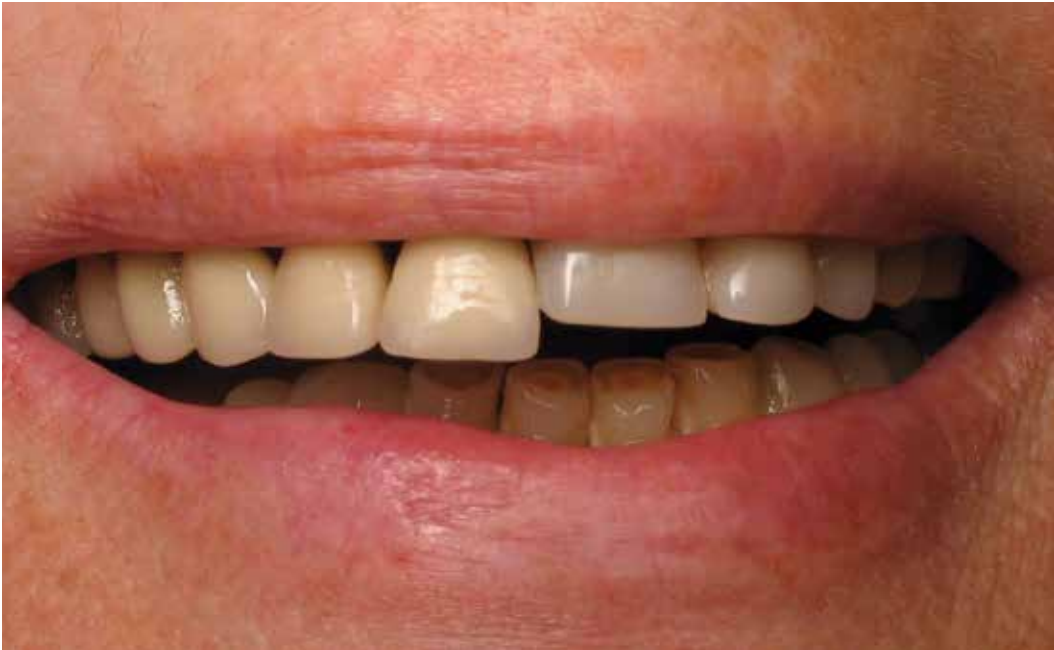

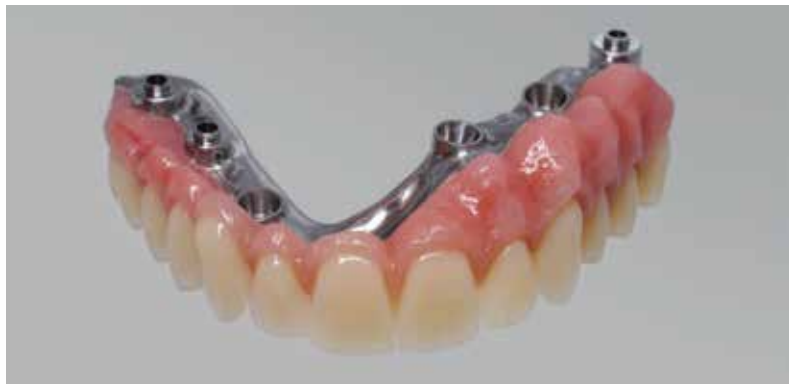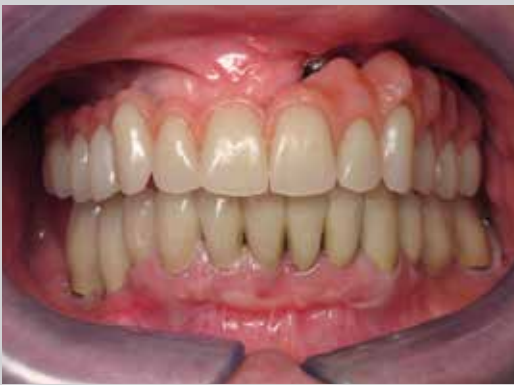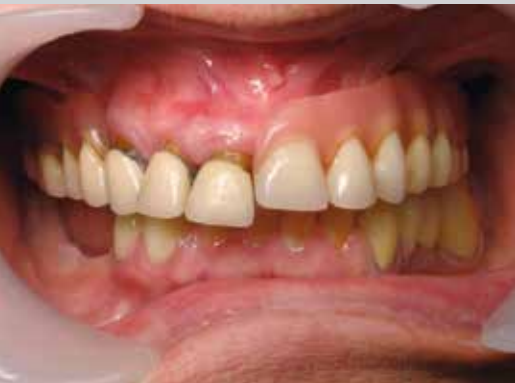Yves Gastard, DT
Pôle d'Odontologie et de
Chirurgie Buccale du CHU
Rennes, France

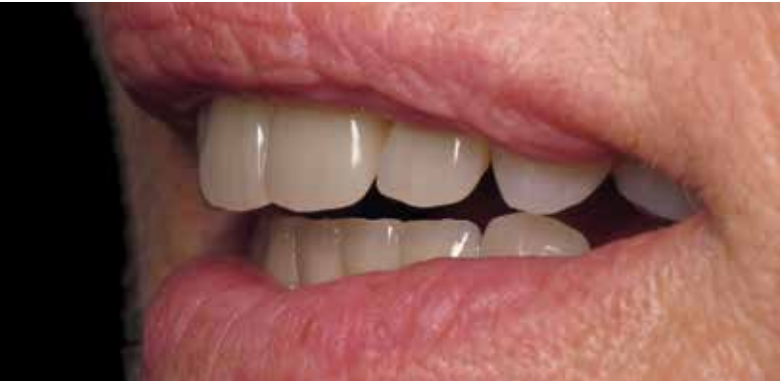

Dr Guillaume Lance
Caen, France

"Due to the excellent interaction of the lower jaw restoration made of ceramic and the upper jaw restoration made of composite resin, the implant structures are very robust. Screw-retained, milled bars impart optimum strength to the upper denture. This treatment approach takes both functional and esthetic aspects into consideration."







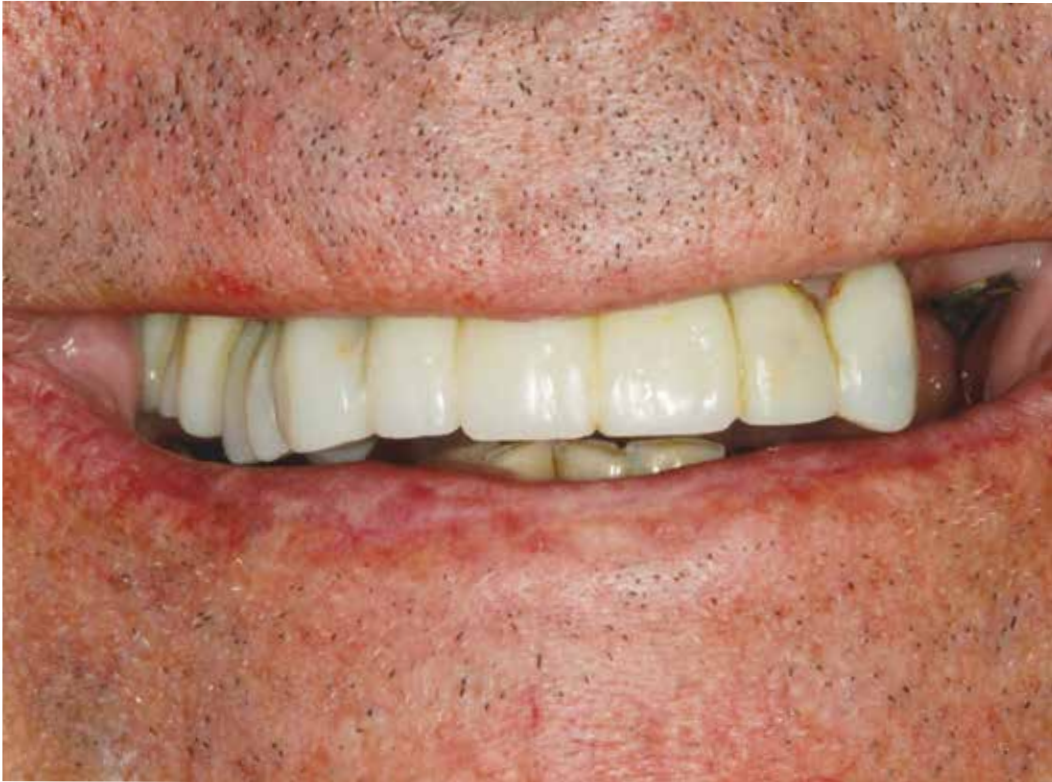

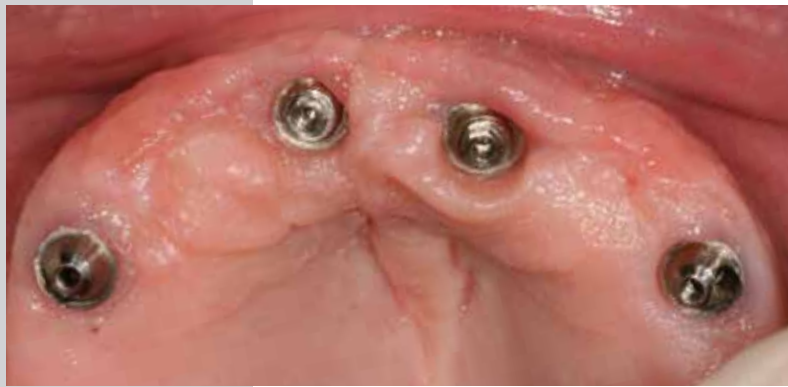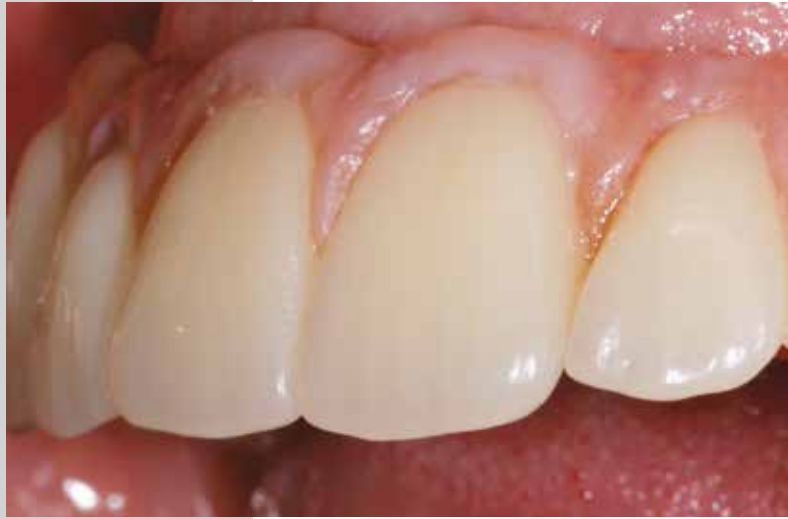Jean-Yves Ciers, DT
Sévrier, France

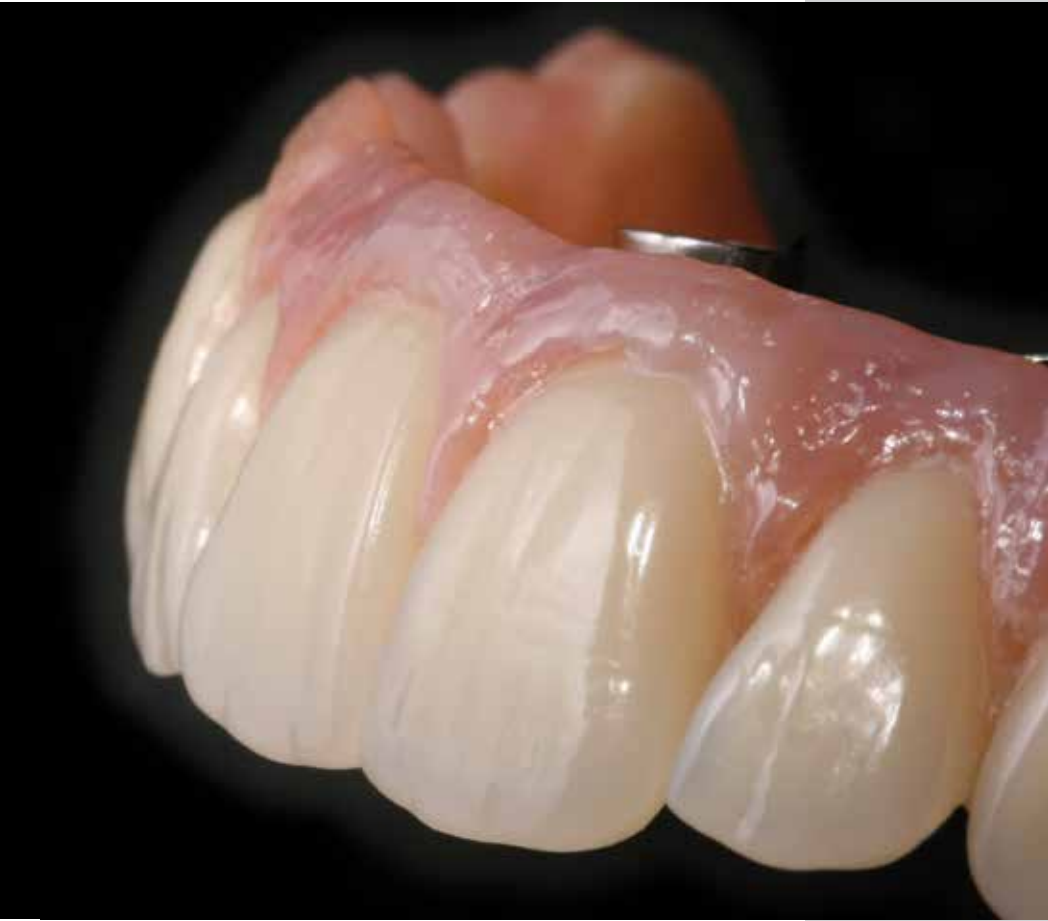

Dr Philippe Gerentes
Lyon, France

"The fabrication of implant-retained dentures requires a considerable amount of skill. Outstanding teamwork between the dental technician and the dentist is key. Exceptional results can only be achieved if all the parties involved work together well."





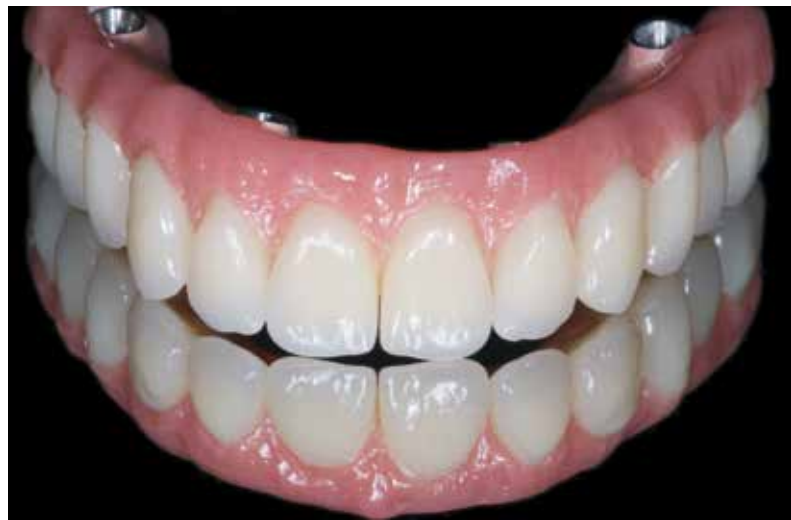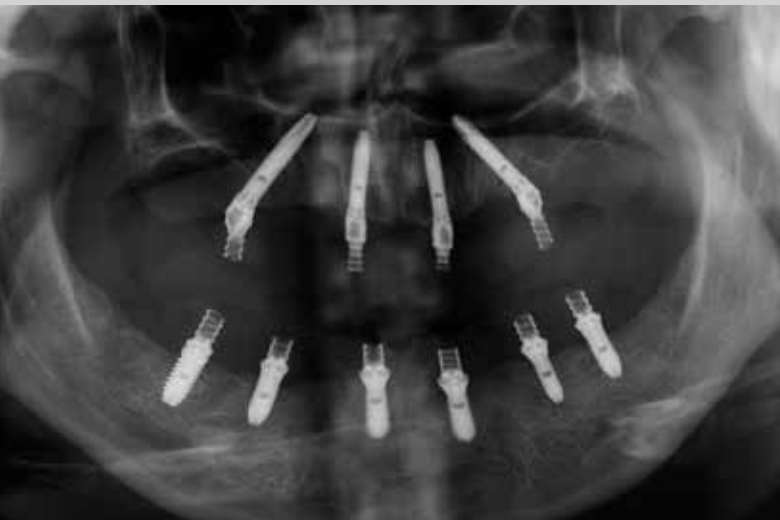



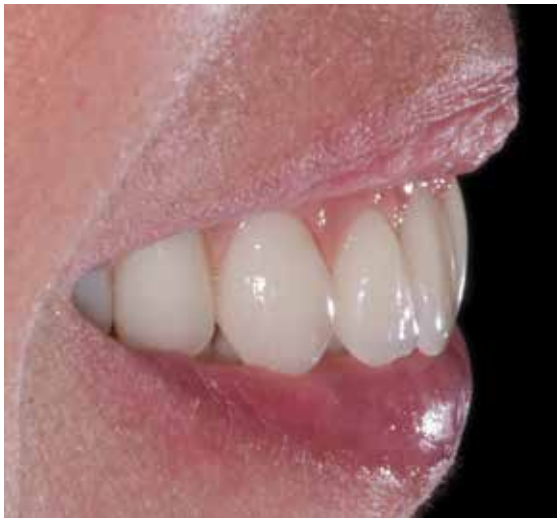
Dr Enrico Agliardi
Bollate (Mi), Italy

"Resin teeth of the latest generation will satisfy the high esthetic expectations of patients, even in completely edentulous cases."







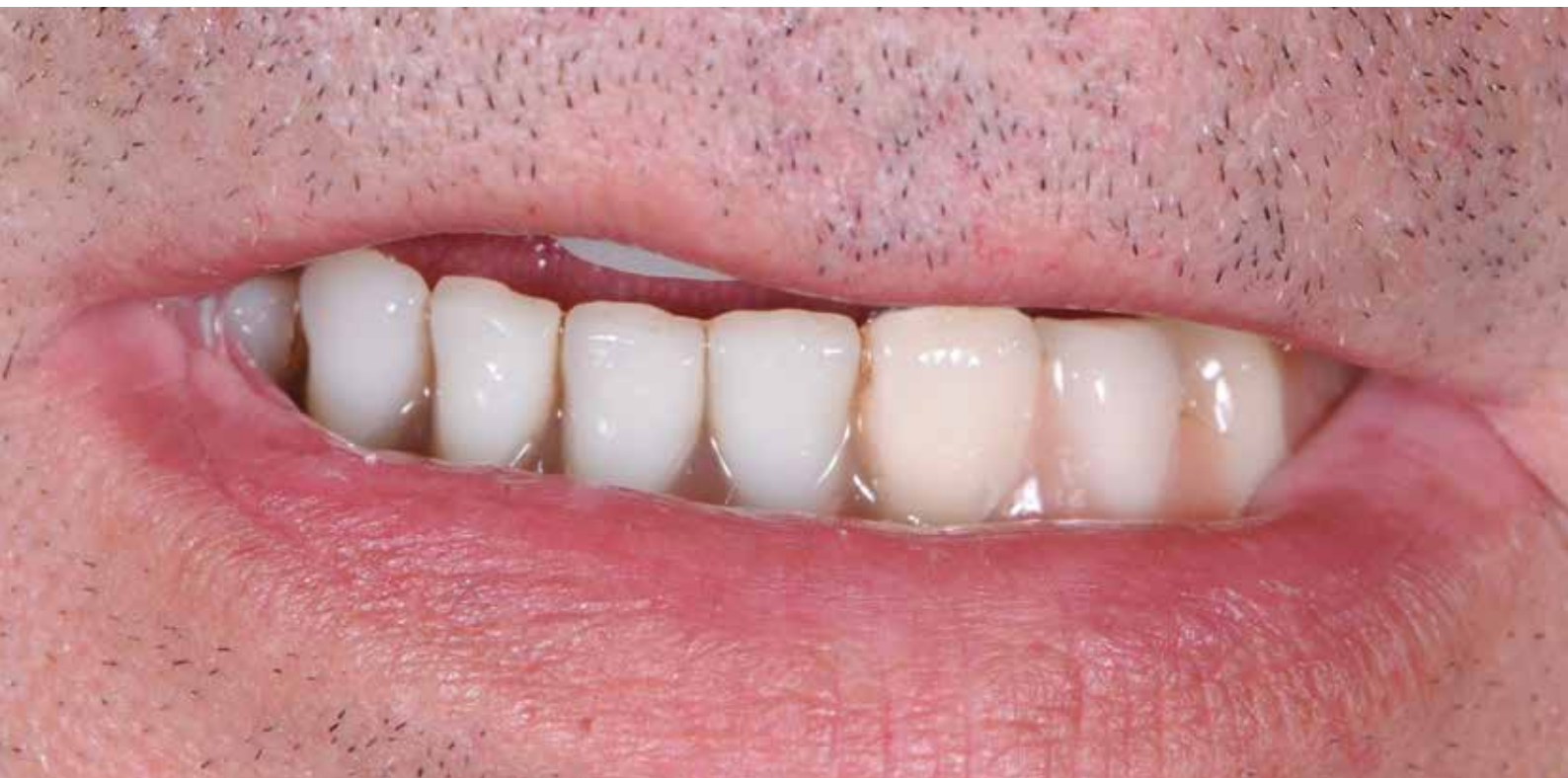

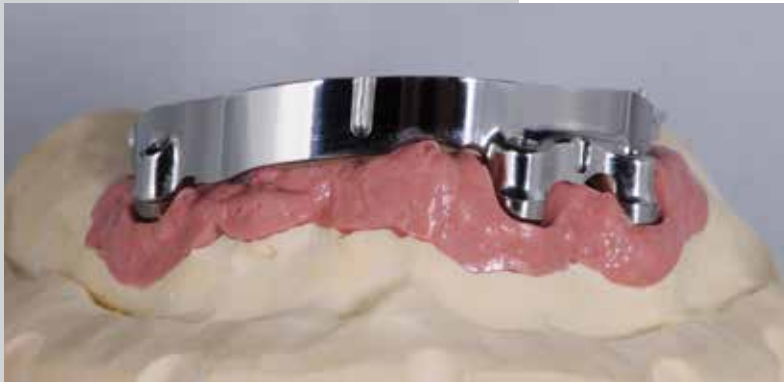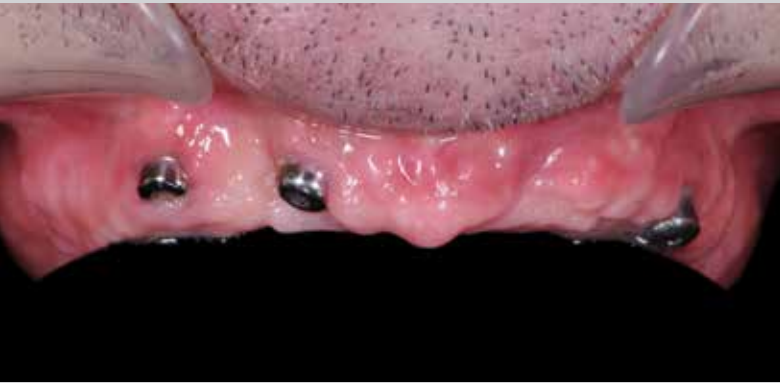Dr Nicolae Iuga
Cluj-Napoca, Romania

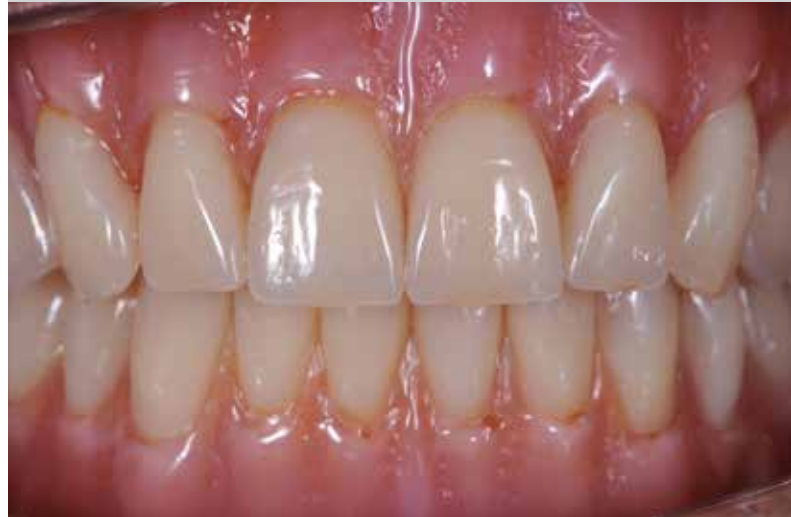

Christian Petri, DT
Cluj-Napoca, Romania

"The restoration of a complete dentition represents a major challenge for any dental professional. Nevertheless, the IvoBase system and the Phonares II resin teeth make this task considerably easier and reliable. The laboratory composite SR Nexco enhances the overall restoration result and produces esthetic and predictable outcomes."







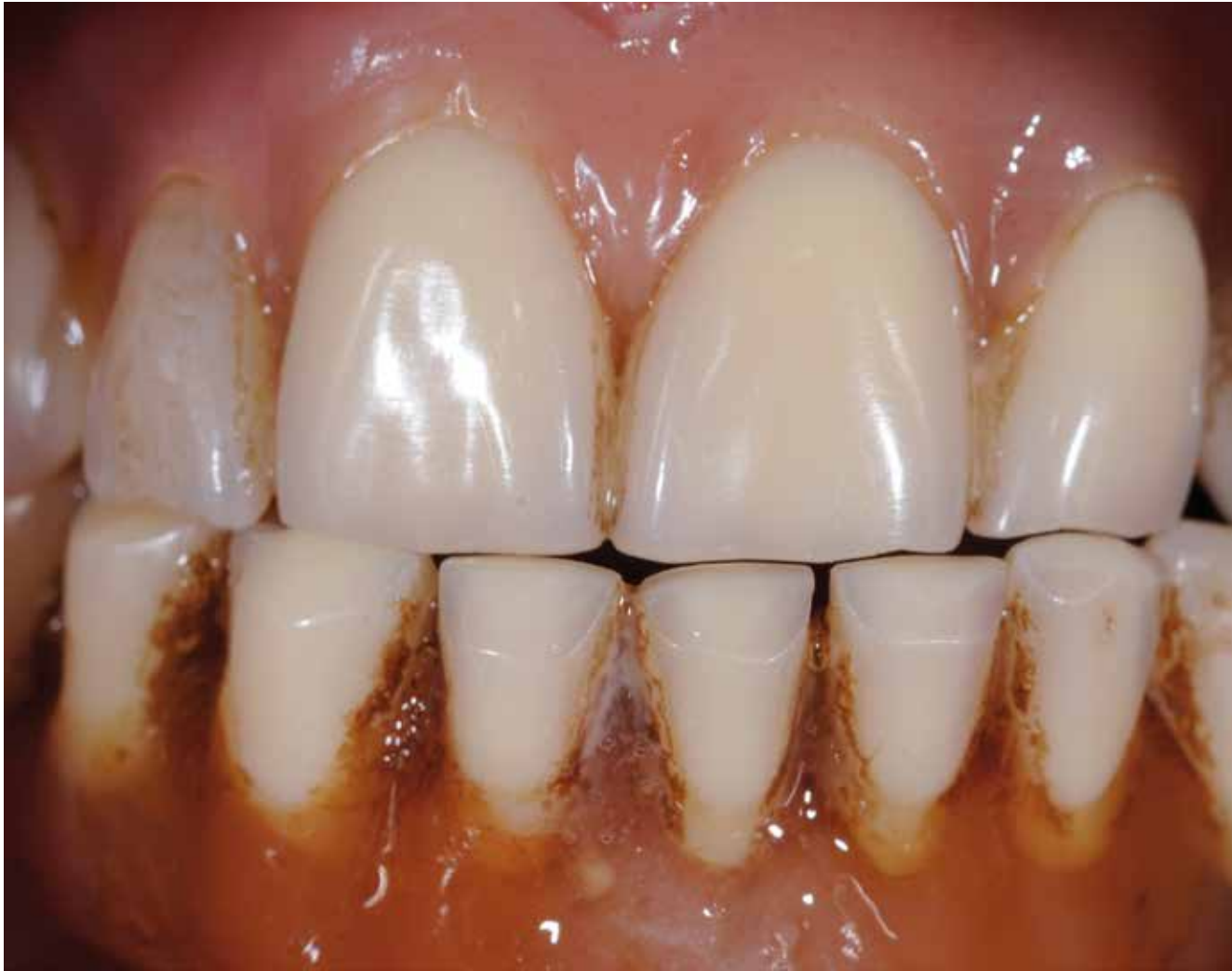

Pasquale Lacasella, DT
Bari, Italy

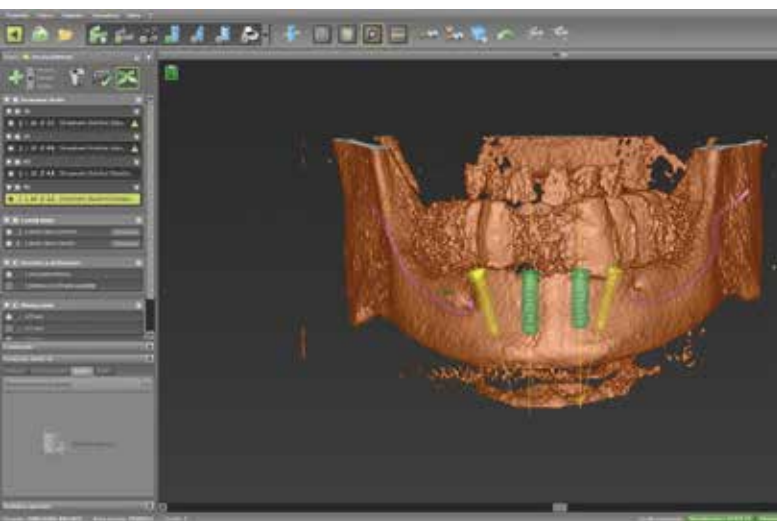


Dr Pietro Venezia
Bari, Italy

"All the data of the provisional denture was transferred to the permanent removable denture with the help of the cross-mounting technique. The restoration was checked in terms of esthetics and function. Then, a screw-retained implant denture for immediate loading was created for the lower jaw. The anterior and posterior parts of the restoration were fabricated with SR Phonares II and the IvoBase system. These two components produce relatively cost-effective, high-performance implant-supported dentures."





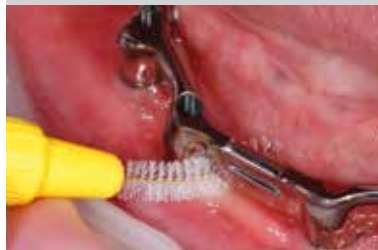
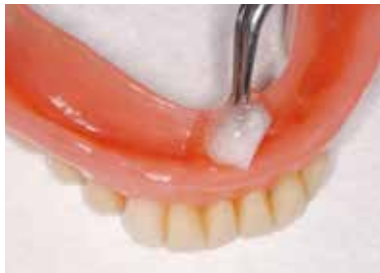
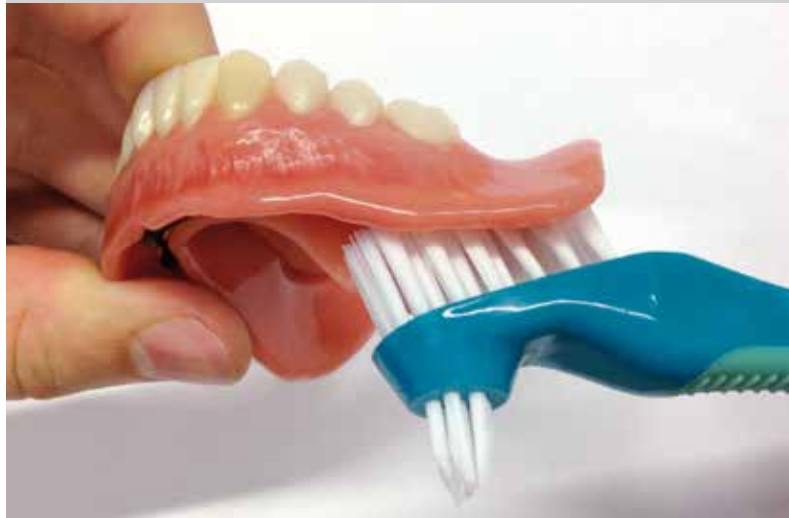
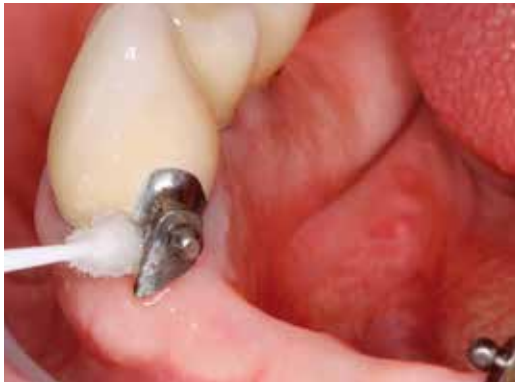
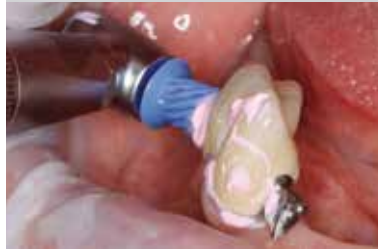Dr Frank Zimmerling
Ivoclar Vivadent AG,
Schaan, Liechtenstein

Hygiene notes:

"Healthy oral conditions constitute the basis for the long-term function and esthetics of teeth and dental restorations. Comprehensive oral health management including at-home oral health measures and professional care ensures a long-lasting outlook in terms of function and esthetics."



www.ivoclarvivadent.com

Ivoclar Vivadent AG

Bendererstr. 2 | 9494 Schaan | Liechtenstein | Tel.: +423 235 35 35 | Fax: +423 235 33 60

