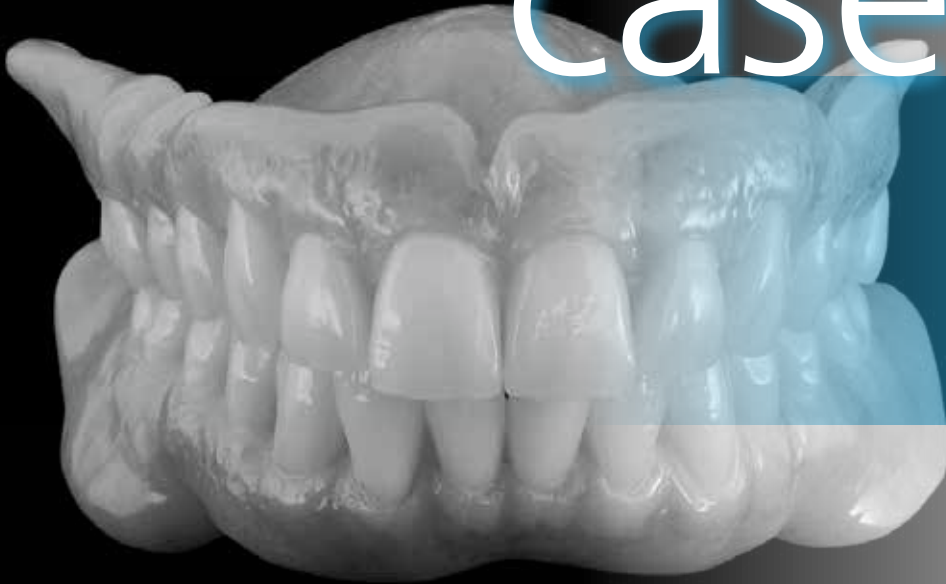

Clinical

casebook

Removable
Prosthetics



Impressions



List of cases

Case 1:

Jean-Yves Ciers, DT

France

6

Case 2:

Pasquale Lacasella, DT, and Dr Piero Venezia

Italy

10

Case 3:

Kyoko Kokubo, DT, and Dr Jiro Abe

Japan

14

Case 4:

Yves Gastard, DT, and Dr Xavier Ravalec

France

18

Case 5:

Christian Hannker, MDT, and Dr Sabine Hopmann

Germany

22

Case 6:

Dr Radhakrishnan Vasudevan

India

26

Hygiene notes:

Dr Frank Zimmerling

Liechtenstein

30

SR Phonares® II prefabricated teeth were used in all the cases shown. The denture base and the denture teeth were characterized with the laboratory composite SR Nexco®.

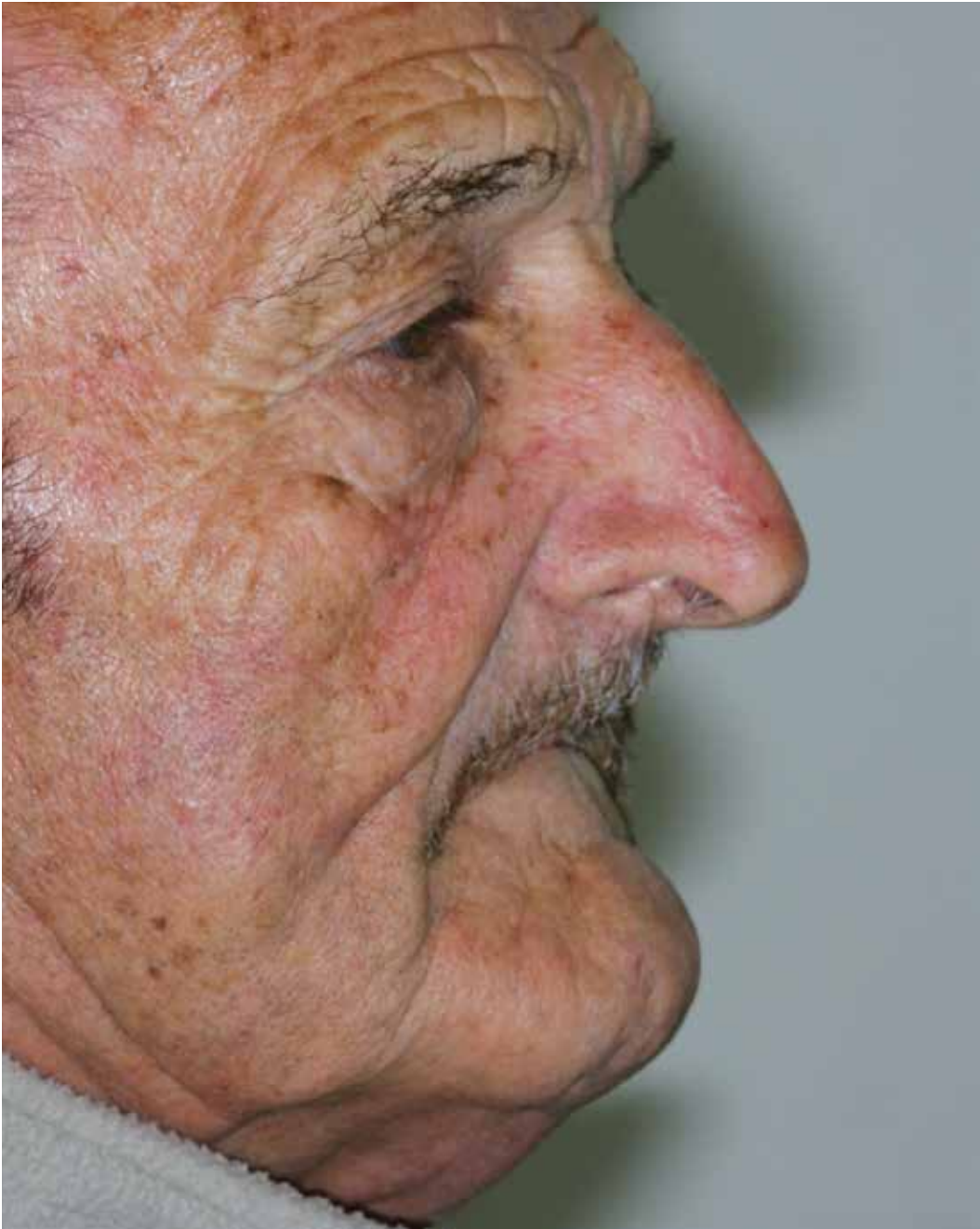For a lasting smile

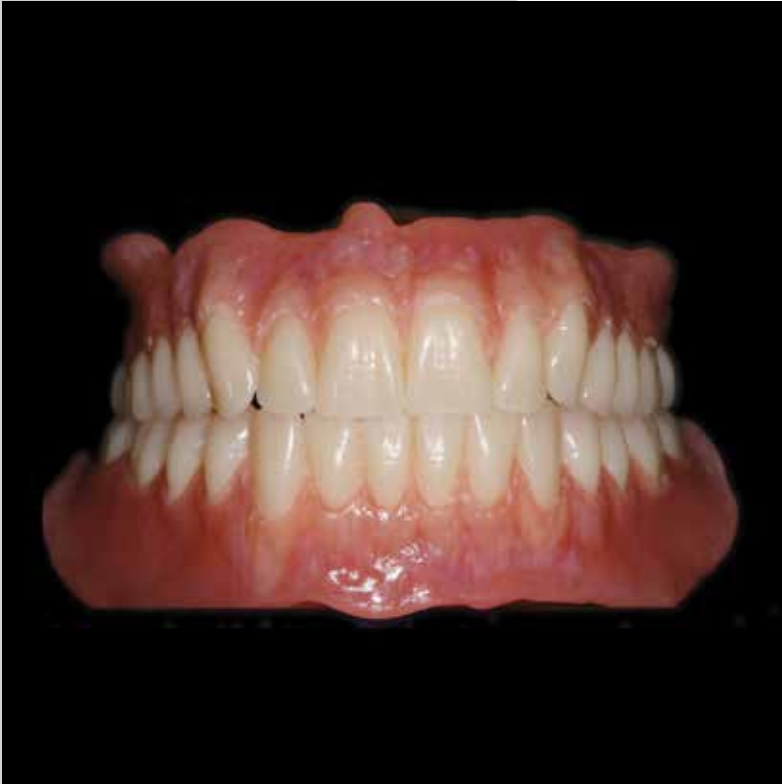Many patients wish to regain a carefree smile. In these cases, removable dentures offer innovative solutions. Irrespective of the starting situation, fully coordinated products help to produce esthetic and functional high-quality results. The ultimate goal is not only to restore the patients' smile, but also their self-confidence.

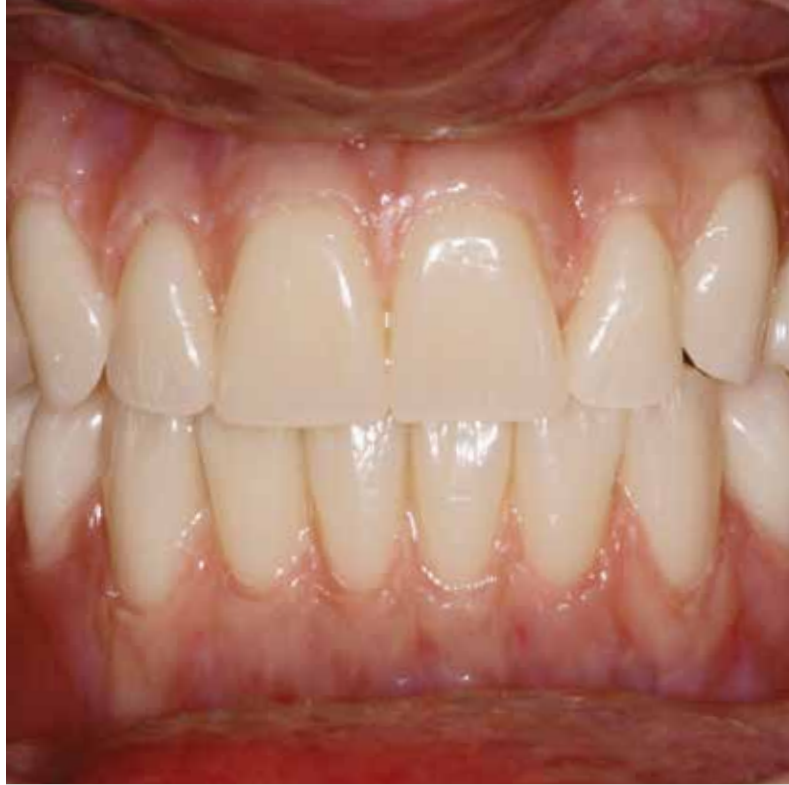
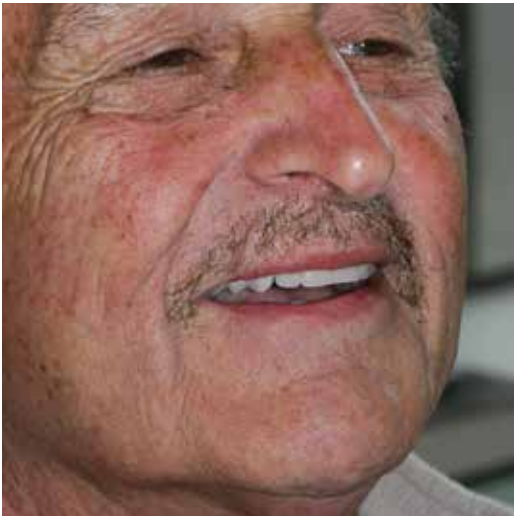
Jean-Yves Ciers, DT
Sévrier, France

"Patients want precision restorations that are comfortable and esthetic at the same time. These requirements can be reconciled with today's prosthodontic materials. They achieve sturdy, long-lasting and esthetic results."







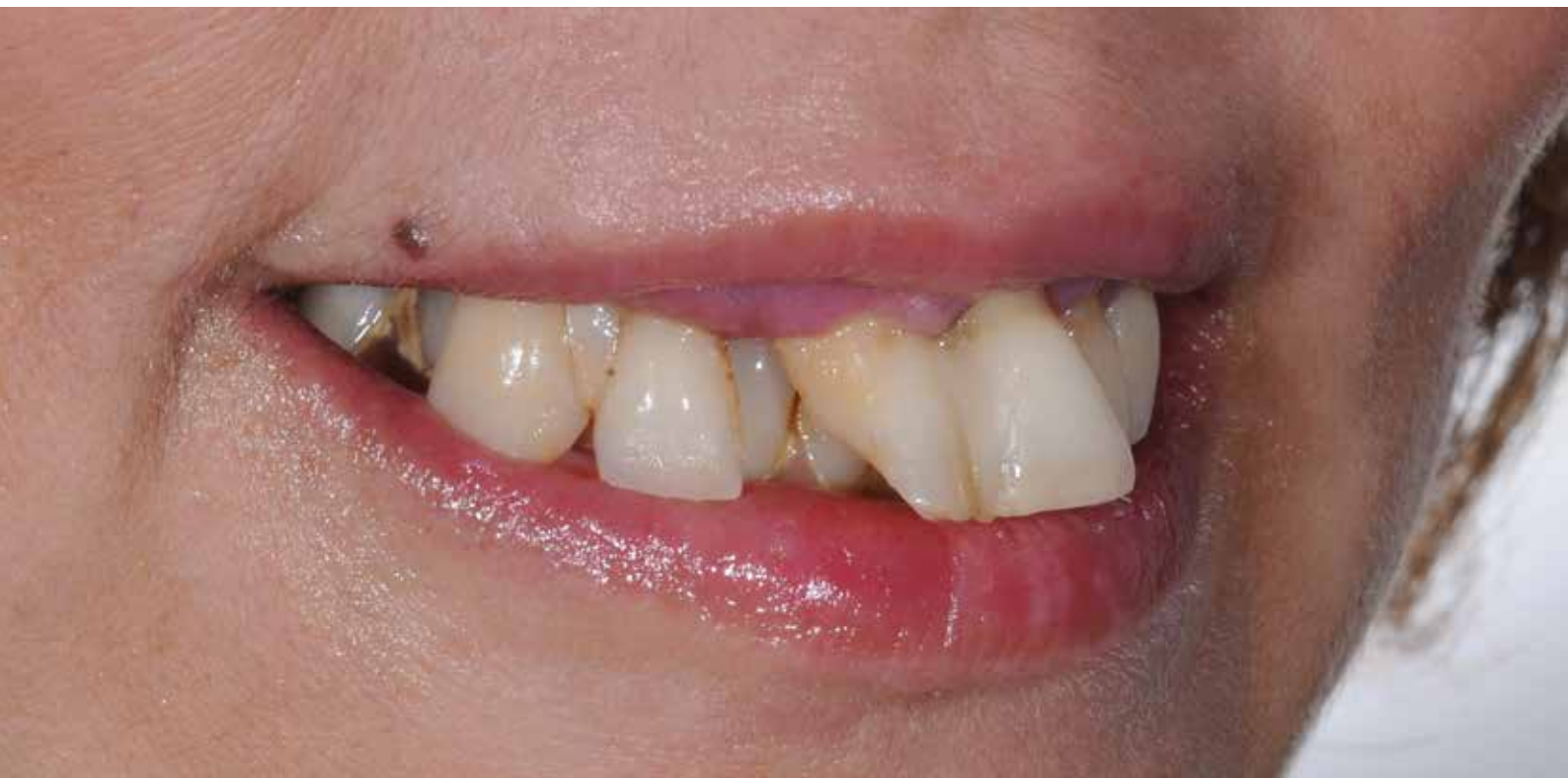

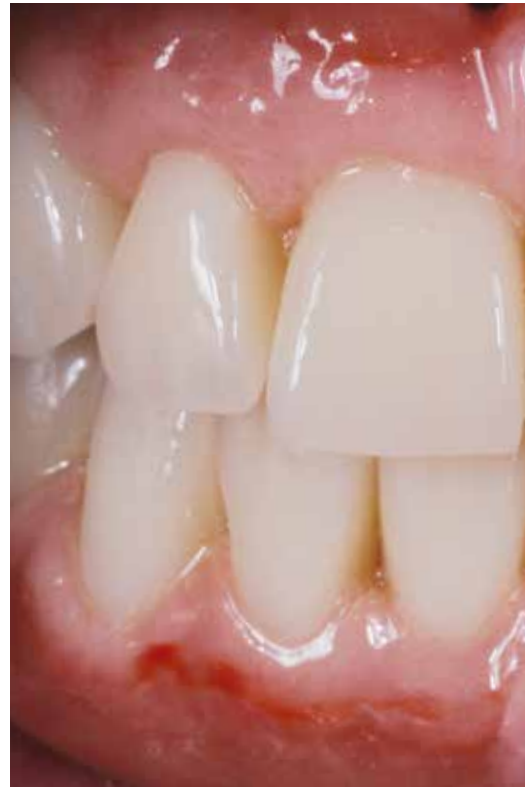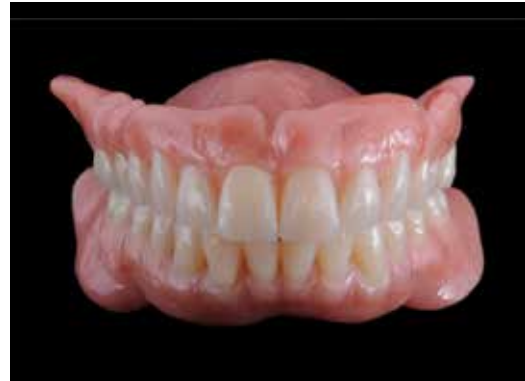Pasquale Lacasella, DT
Bari, Italy

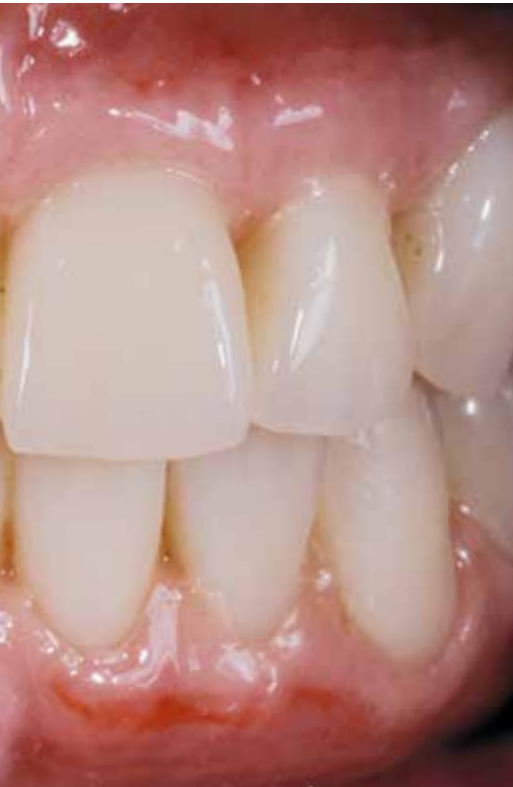

Dr Piero Venezia
Bari, Italy

"The patient received full dentures in the upper and lower jaw. Due to the new SR Phonares II tooth range and the IvoBase system, the dentition was restored esthetically and functionally. Today, the young patient is able to lead a normal social life again."







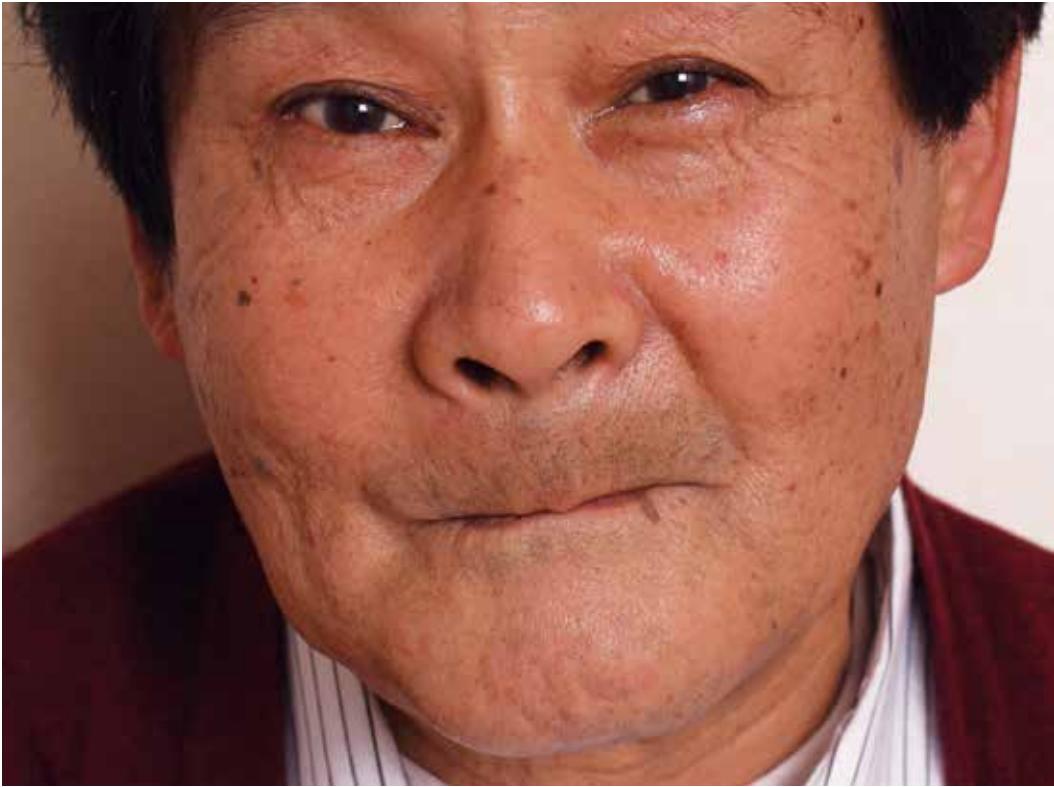


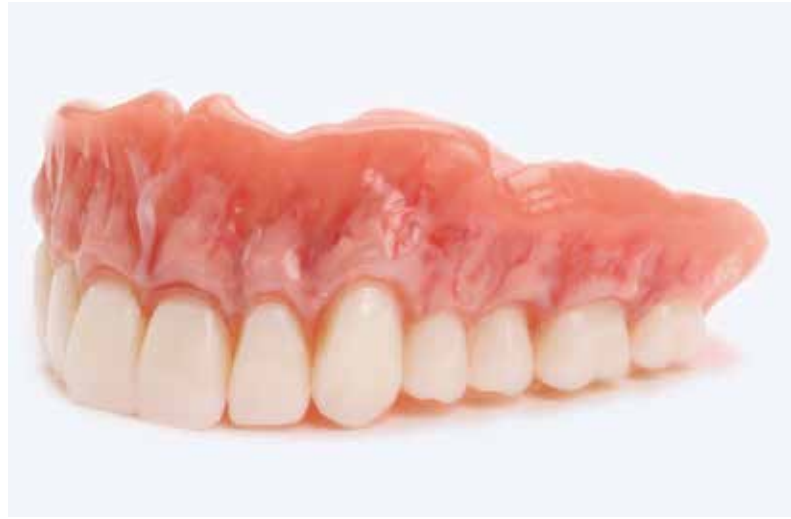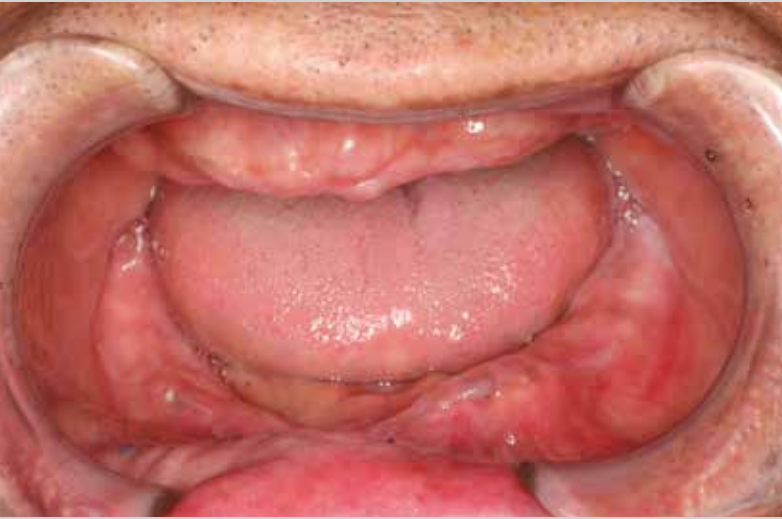Kyoko Kokubo, DT
Tokyo, Japan

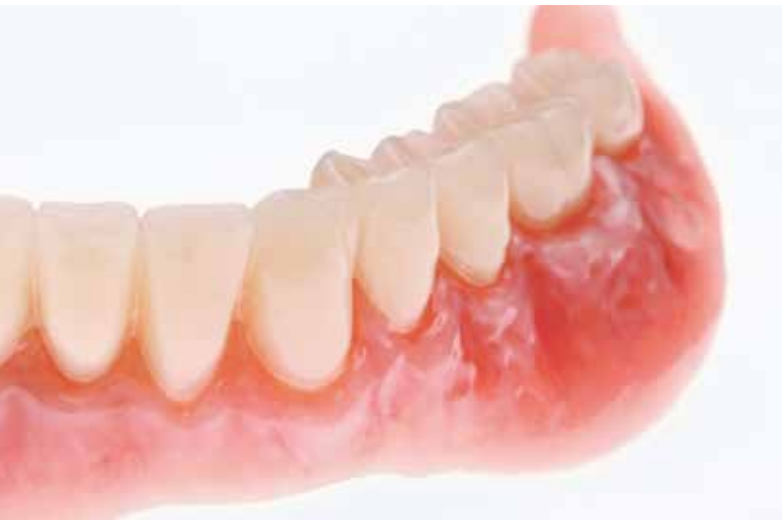

Dr Jiro Abe
Tokyo, Japan

"Everyone wants to look great and maintain their natural good looks – regardless of whether this applies to existing or artificial teeth. Good looks give us the energy, courage and self-confidence that we need in order to successfully engage with our social environment."







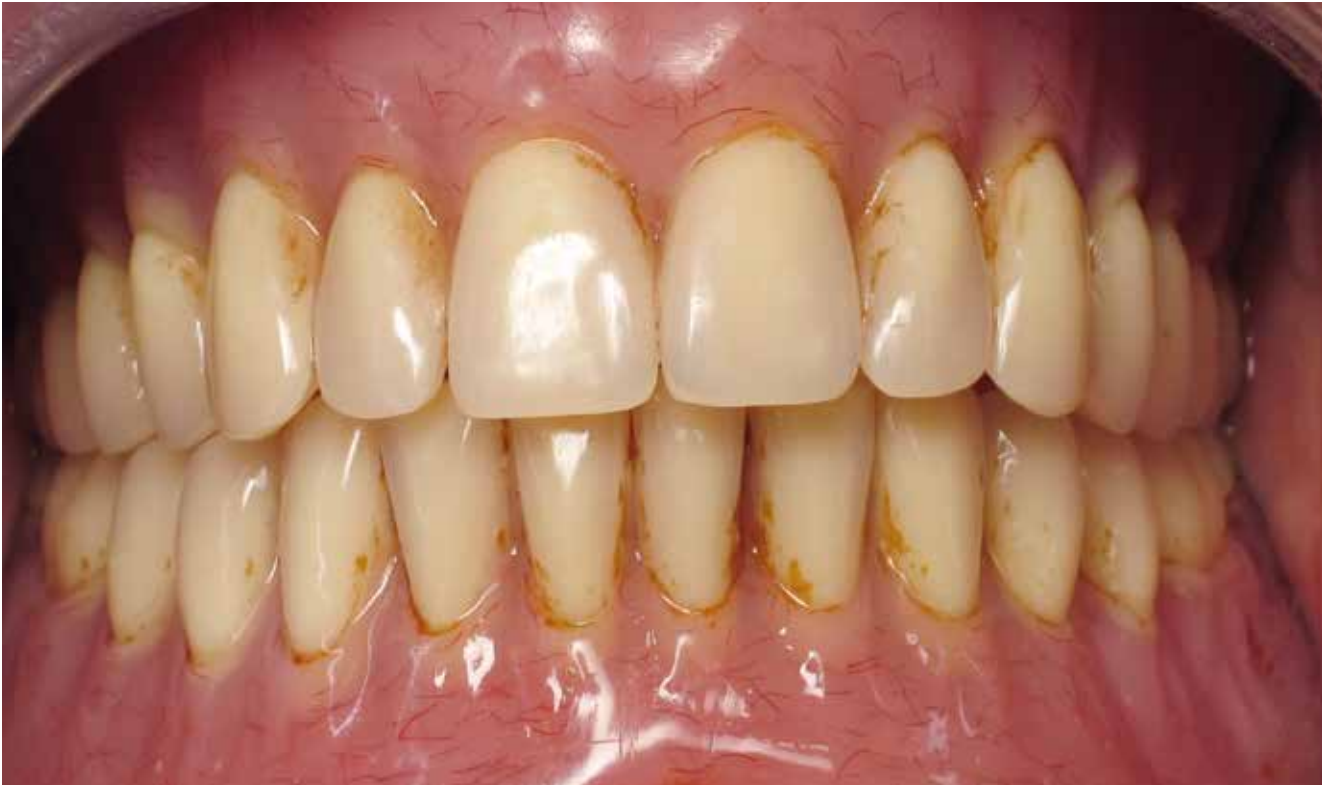

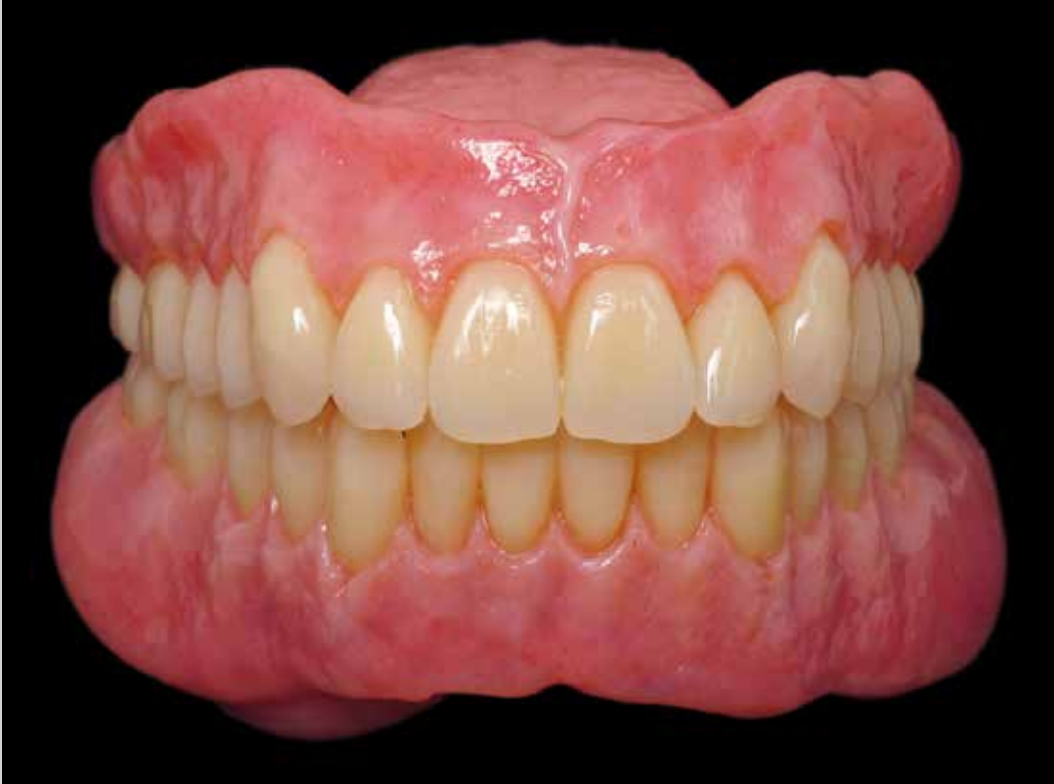Yves Gastard, DT
Pôle d'Odontologie et de
Chirurgie Buccale du CHU
Rennes, France

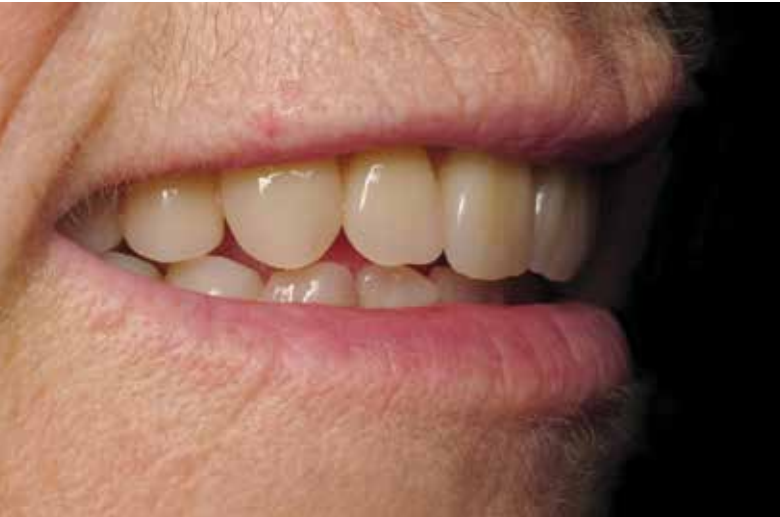

Dr Xavier Ravalec
Saint-Grégoire, France

"Excellent adjustment of the denture base to the oral mucous membrane and an outstanding occlusion enhance the esthetic outcome."







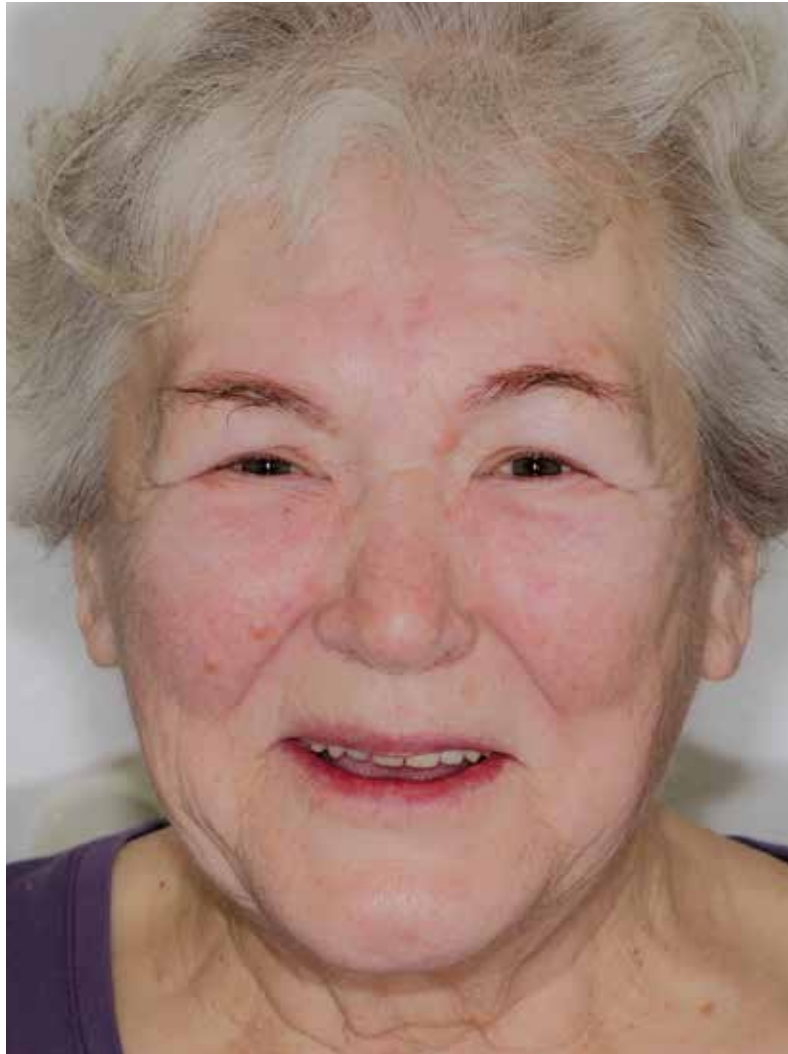

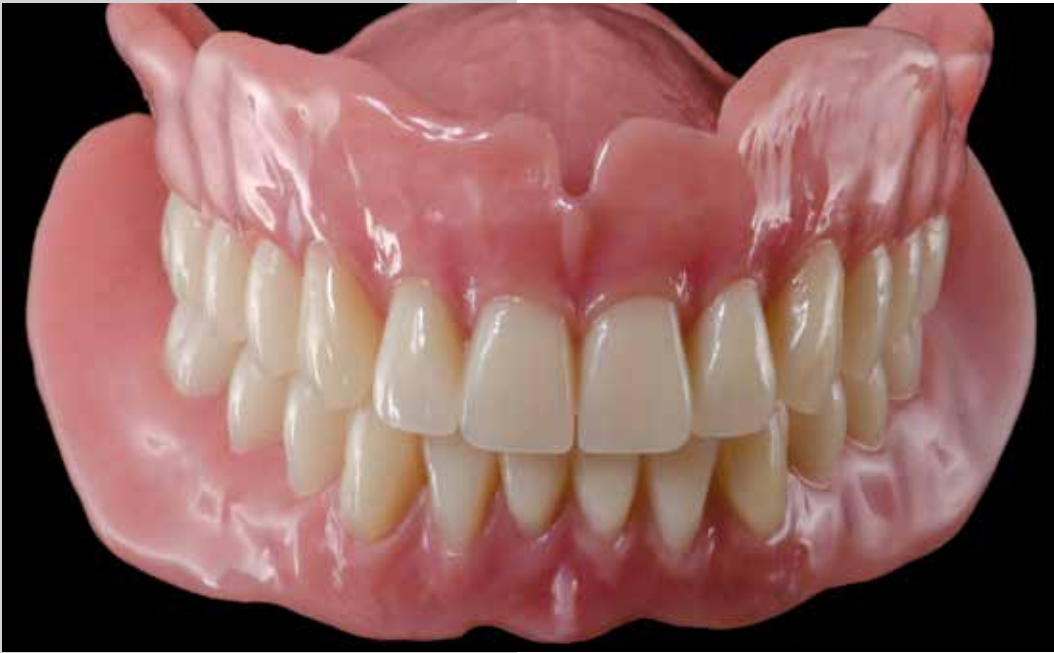Christian Hannker, MDT
Rastede, Germany

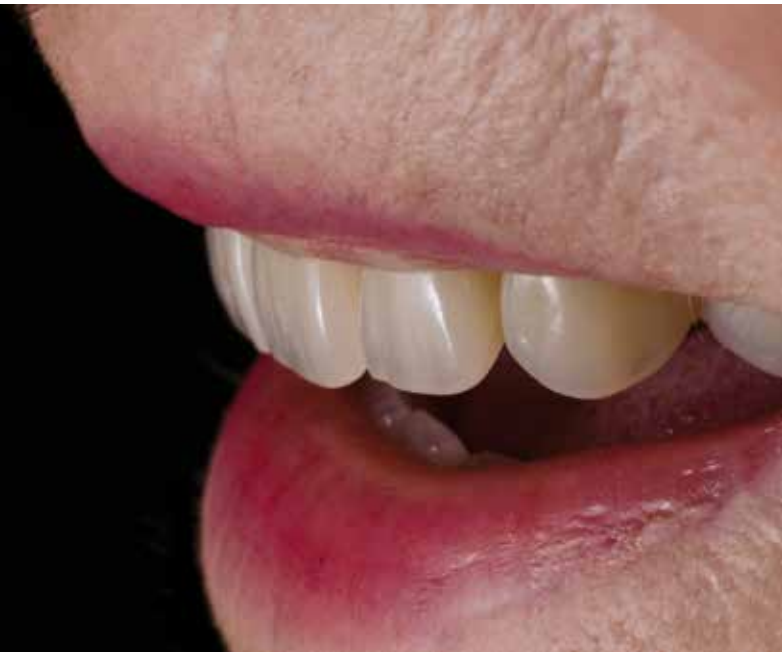

Dr Sabine Hopmann
Lemförde, Germany

"This patient is an excellent example of how attractive teeth and a style make-over can influence the personality of an individual. The natural charm of this patient is enhanced by the individually created dental restorations. The SR Phonares II teeth enable the endless variety of tooth shapes and positions to be reconstructed. Furthermore, the IvoBase system ensures optimized fit of the denture base, which contributes to the patient's chewing and speaking comfort. The patient is clearly satisfied with her new teeth."





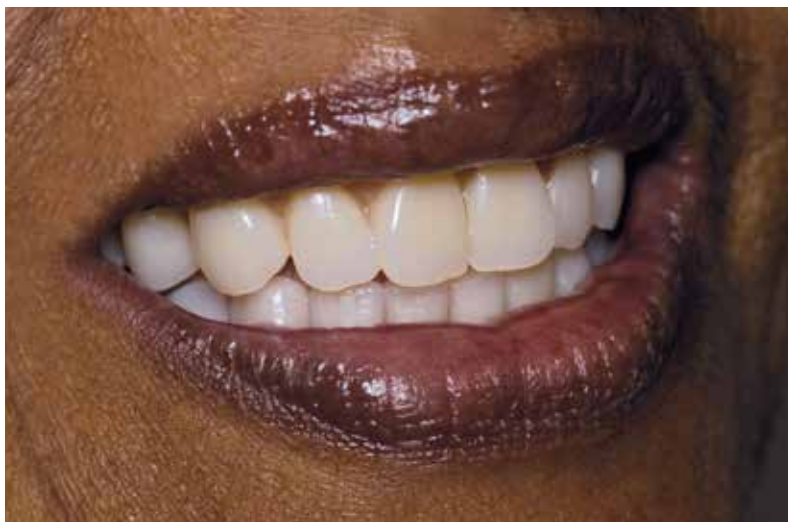
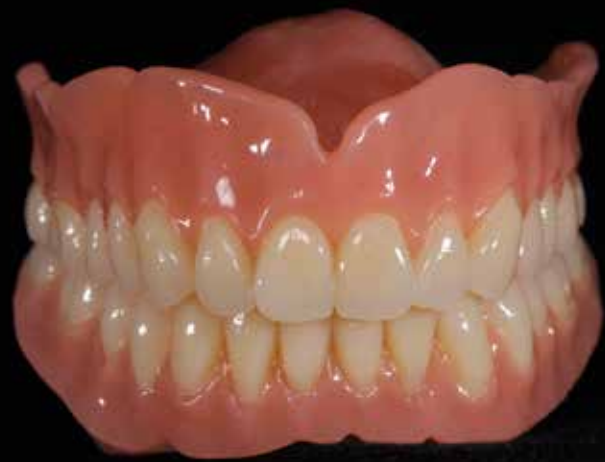


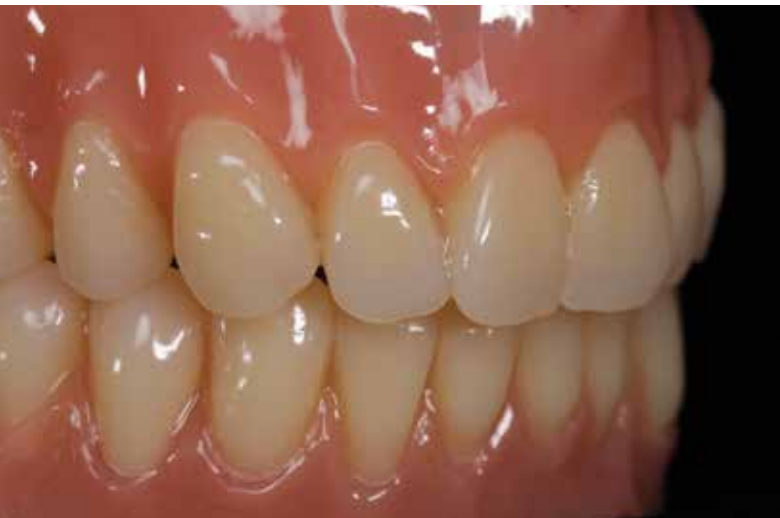Dr Radhakrishnan Vasudevan
Chennai, India

"A 70-year-old patient whose dentures fit very poorly presented to our practice. She was most concerned about the unnatural appearance of the artificial teeth. Moreover she was dissatisfied with the functional aspects of the restorations. Due to the poor fit of the denture, very painful ulcers had formed. In order to satisfy her esthetic and functional requirements, we decided to provide her with BPS dentures featuring Phonares teeth."





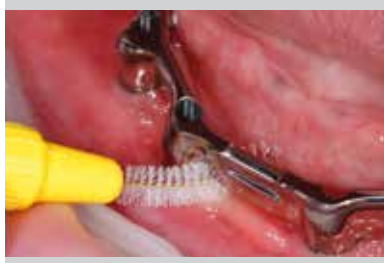
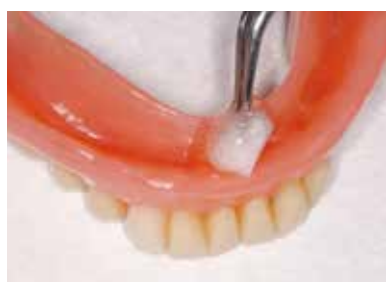
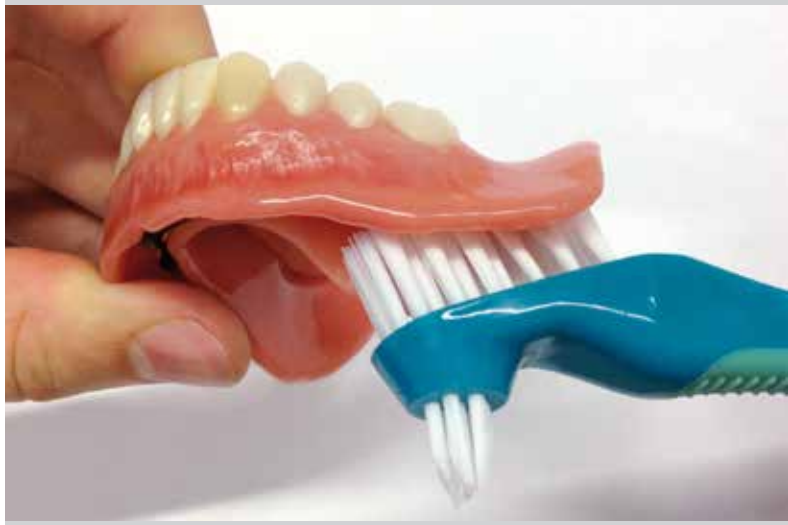
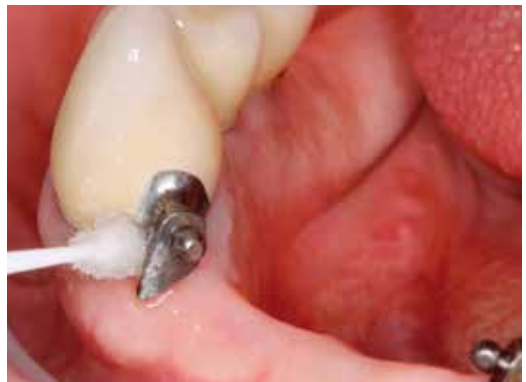
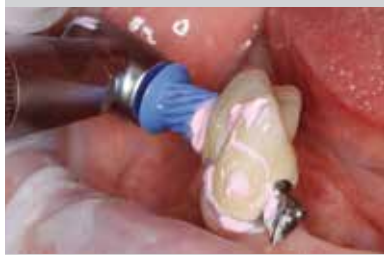Dr Frank Zimmerling
Ivoclar Vivadent AG,
Schaan, Liechtenstein

Hygiene notes:

"Healthy oral conditions constitute the basis for the long-term function and esthetics of teeth and dental restorations. Comprehensive oral health management including at-home oral health measures and professional care ensures a long-lasting outlook in terms of function and esthetics."



www.ivoclarvivadent.com

Ivoclar Vivadent AG

Bendererstr. 2 | 9494 Schaan | Liechtenstein | Tel.: +423 235 35 35 | Fax: +423 235 33 60

