



Warning: highly addictive!

Tetric EvoCeram® Bulk Fill
and Bluephase® Style

A handwritten signature in black ink, appearing to read 'M. Lenhard', written over a white background.

Dr Markus Lenhard
Dentist

Warning: highly addictive!

Over the past few years, filling composites have been considerably improved in terms of their esthetics, wear resistance and other physical properties. These new composite resins permit a defect-oriented approach to restoring carious lesions. They are also easier to repair and in many cases offer a more economical alternative to other restorative materials.

As composite resins have replaced amalgam as the most popular filling material in many countries, it is now important to consider the relative life expectancy of composite fillings compared with those made of amalgam and other dental materials. An analysis of the survival rate of posterior restorations, which is based on insurance claims data from 1993 to 2000 (Bogacki et al. 2002) shows that the risk of losing a composite resin filling is negligibly higher than that of an amalgam filling.

Nevertheless, it should be noted that the study was conducted within a timeframe in which records suggest that a large percentage of the composite resin fillings placed may not have been properly polymerized. The way in which to achieve successfully polymerized fillings continues to be a highly underrated task that is difficult to standardize in clinical practice. Since polymerization directly affects practically all the physical parameters of composite resins, this is an area in which considerable improvements could still be made, which would presumably help to increase the life of composite restorations.

In a direct comparative study spanning twelve years, Opdam et al. (2012) reported that the survival rate for composite resin fillings was better than that of amalgam fillings. Lange and Pfeiffer (2009) did not find any clinically relevant differences between mod-restorations made of ceramics and of composites after 57 months. Clinical investigations have shown that composite resins also produce excellent results when they are used for cusp coverage (Deliperi and Bardwell 2009; Opdam et al. 2008).

Studies from all over the world show that more often than assumed, curing lights do not emit the required light intensity.

Author	Country	Number of devices tested	Number of devices that emitted less than 400 mW/cm ²
Matošević, Tarle (2011)	Croatia	111	44 %
Mahn (2008)	Chile/Peru	90	45 %
Barghi (2007)	USA	161	36 % less than 500 mW/cm ²
Ernst (2006)	Germany	659	26 %
El-Mowafy (2005)	Canada	214	30 %
Santos (2005)	Brazil	120	85 %



Initially, composite resins were only used for placing small fillings. Today, however, they are increasingly used for larger restorations involving cusps (Deliperi and Bardwell 2006; Kujis et al. 2006; Opdam 2008). Therefore, the indications of these materials now overlap with those of indirect all-ceramics. Ultimately, however, the decision on which type of material is preferred rests on the technical feasibility of using a direct or indirect procedure in the given situation.

The physical properties of composite resins have been gradually improved over the years as a result of the ongoing demand of dentists for simpler filling techniques. Lately, most of the leading dental manufacturers have introduced what are known as “bulk filling” materials. While conventional composites have to be applied in layers of only two millimetres and a maximum of three millimetres, these new bulk filling materials can be placed in increments of up to four or five millimetres. As a result, dental professionals have to place considerably fewer layers to fill a tooth. Small to medium size cavities can be efficiently restored with only one or two increments.

Even though this all sounds very appealing, two important factors have to be considered:

- Firstly, can thick layers of this kind be adequately polymerized?
- Secondly, how does the large volume of the layer affect the shrinkage stress of the filling and the precision of the restoration margins?

In addition to these two parameters that are crucial to the longevity of the restoration, other factors have to be taken into account, for example, the polishing properties and the esthetic potential of these materials. I would like to take this opportunity to provide a short evaluation of “bulk filling” materials on the basis of the available data and to present the clinical application spectrum of Tetric EvoCeram® Bulk Fill in my dental practice.

First of all, it is important to note that “bulk filling” materials do not constitute a uniform class of materials. While the essential characteristic, that is, the ability to apply the material in thick increments is a common theme among these materials, there are many differences related to the clinical application and the way in which the fillings are built up.

Survey of “bulk filling” materials

Product	Manufacturer	Consistency	Permissible increment thickness	Clinical application
Tetric EvoCeram Bulk Fill	Ivoclar Vivadent	Sculptable	4 mm	Single-layer technique is possible
Venus Bulk Fill	Heraeus Kulzer	Flowable	4 mm	Has to be coated with a conventional composite resin
SDR	Dentsply	Flowable	4 mm	Has to be coated with a conventional composite resin
SonicFill	Kerr	Flowable, sound activated, sculptable	5 mm	Single-layer technique is possible
x-tra fil	Voco	Sculptable	4 mm	Single-layer technique is possible
x-tra base	Voco	Flowable	4 mm	Has to be coated with a conventional composite resin

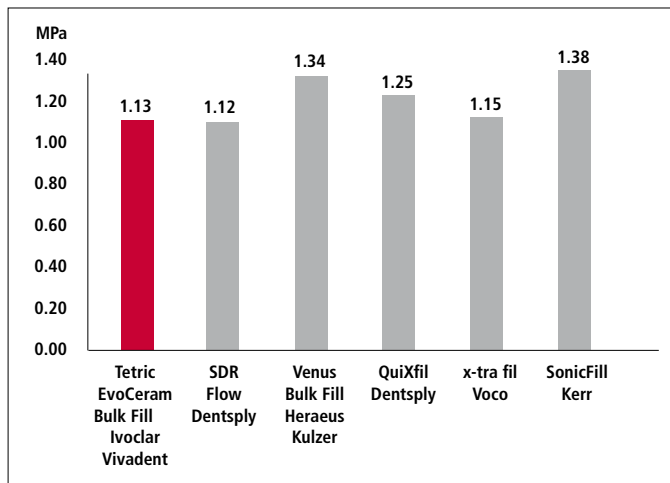
The main requirements that a filling material must satisfy are listed below:

- Low shrinkage stress and therefore marginal integrity
- Adequate resistance to chewing forces in the posterior dentition
- Wear resistance
- Excellent sculpting properties
- Adequate working time under ambient light
- Adequate radiopacity
- Good polishing properties and esthetic integration in the cavity

Shrinkage stress

One of the prerequisites that a bulk filling material must fulfil is that it should not shrink unduly and cause the formation of marginal gaps.

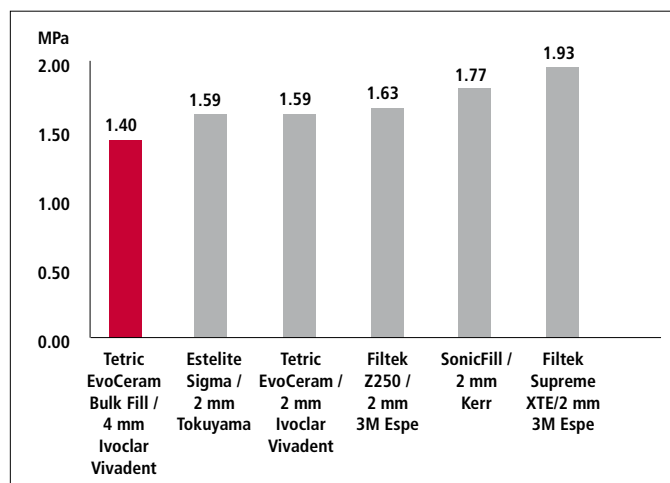
Shrinkage stress



As measured by Watts in increments of 0.8 mm, R&D Ivoclar Vivadent, June 2011

The shrinkage stress in a 2-mm thick filling placed with a conventional direct composite resin and in a 4-mm thick Tetric EvoCeram Bulk Fill filling is at least equal.

Build-up of shrinkage stress in a 4-mm thick increment of Tetric EvoCeram Bulk Fill compared with that of a 2-mm thick increment of a conventional composite resin.

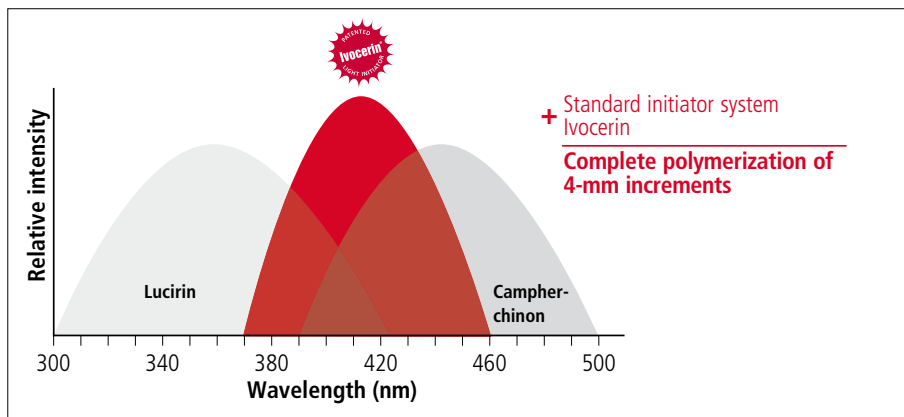


As measured by Watts in increments of 2 or 4-mm, R&D Ivoclar Vivadent, June 2011

In another study in which Tetric EvoCeram® (placed in 2-mm increments) was compared with Tetric EvoCeram Bulk Fill (placed in 4-mm increments), no significant difference in the margin behaviour in the materials was recorded after occlusal loading (Frankenberger 2011, personal communication).

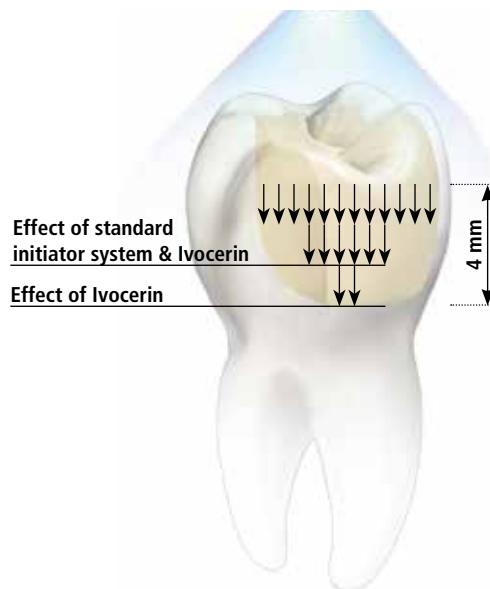
Photo-initiators

The bulk filling materials on the market contain different types of photo-initiators. These curing agents transform monomers into polymers. When they are exposed to light, photo-initiators break down, thereby triggering the polymerization of the monomer. Conventional systems usually contain the popular light-activator camphorquinone or even Lucirin. Tetric EvoCeram Bulk Fill, however, features an additional highly reactive photo-initiator called Ivocerin, a proprietary development of Ivoclar Vivadent. This component allows increments of 4-mm thickness to be cured in only 10 seconds ($\approx 1,000 \text{ mW/cm}^2$) with Bluephase® Style, for example.



Unlike standard composite resins, Tetric EvoCeram Bulk Fill has an enamel-like translucency of 15 percent. This characteristic is made possible by the photo-initiator Ivocerin. Although considerably fewer photons reach the cavity floor than its surface as a result of this translucency value, this amount is enough for the sensitive Ivocerin photo-initiator to trigger the chemical reaction at a depth of four millimetres and more. A welcome accompanying effect: The well-balanced translucency together with the selective light-refraction indices of the fillers, nanopigments and the monomer matrix ensure excellent adaptation of the restoration shade to the surrounding natural tooth structure without causing the greyish tinge associated with highly translucent composites.

Effect of Ivocerin photo-initiator



Occlusal loading and polymerization

Composite resins that are used to fabricate load-bearing restorations must exhibit a flexural strength of at least 80 – 100 MPa (Illie et al. 2005) to prevent the risk of fracture of the restorations. The flexural strength of Tetric EvoCeram Bulk Fill measures 120 MPa and therefore equals that of Tetric EvoCeram. As a result, it is substantially higher than the minimum requirement.

		ISO 4049	Tetric EvoCeram Ivoclar Vivadent	Tetric EvoCeram Bulk Fill Ivoclar Vivadent
Flexural strength	MPa	≥ 80	120	120
Water absorption (7 days)	µg/mm ³	≤ 40	21.2	21.1
Water solubility (7 days)	µg/mm ³	≤ 7.5	< 1.0	< 1.0
Radiopacity	% Al	100	Bleach I 200 Bleach L, M, XL 300 Other shades 400	260
Other physical properties				
Vickers hardness HV 0.5/30	MPa		580	620
Flexural modulus	MPa		10000	10000
Max. increment thickness (IV method)	mm		1.5–2.0	4.0
Translucency: depending on opacity	%		6.5–20.0	15–17

Physical properties in accordance with ISO 4049

In this context, it is important to bear in mind that the specified flexural strength values are only meaningful if the composite resin can be adequately polymerized by the clinician. If composite resins are cured with insufficient light intensity their physical strength will be automatically compromised. As a result, the restorations will be more susceptible to premature failure (See table on page 2).

Correct polymerization is very technique sensitive in clinical dentistry. Every additional millimetre that separates the filling surface from the curing light decreases the intensity of the light (mW/cm²) which reaches the restoration, due to unavoidable scattering of the light rays. At a distance of 1 cm between the light probe and the filling surface, more than 80 % of the light intensity may be lost (Felix and Price 2003). Focusing or turbo light guides or devices, in which the LED is mounted in the front, have proved to be particularly inconvenient in this respect, since they tend to scatter light farther away from the tip than parallel light guides (Price et al. 2000). Consequently, polymerization units equipped with parallel light guides, such as Bluephase Style, should be given preference.

The short light guide of Bluephase® Style is an additional advantage of this curing device. In many cases, the working environment is very tight. Many patients and children in particular have a small oral cavity, making the back-most molars difficult to reach. Furthermore, most of the cavities are located on distal surfaces. Every clinician can add to the list of situations in which they have had difficulty in reaching a specific treatment area. The light guide of the Bluephase Style has a short bent tip. As a result, it requires less space than conventional devices.

Bluephase Style, Ivoclar Vivadent
Parallel short 10-mm light guide



Bluephase G2, Ivoclar Vivadent
Parallel 10-mm light guide

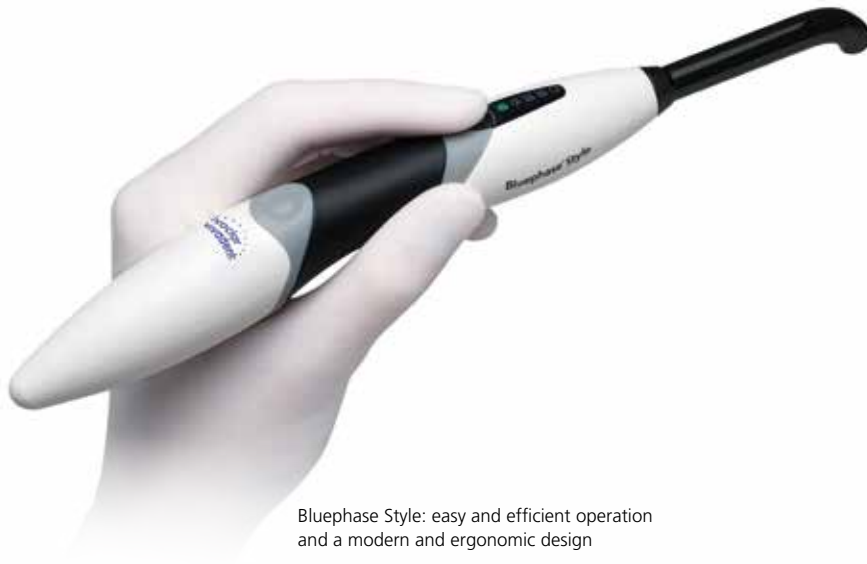

SmartLite PS, Dentsply
LED mounted in the front



Demi Plus, Kerr
Turbo light guide 13 > 8 mm



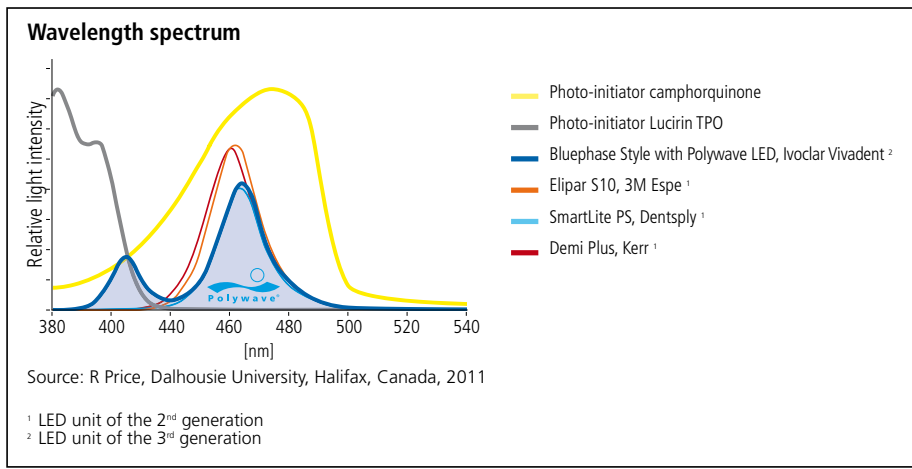


Bluephase Style: easy and efficient operation and a modern and ergonomic design

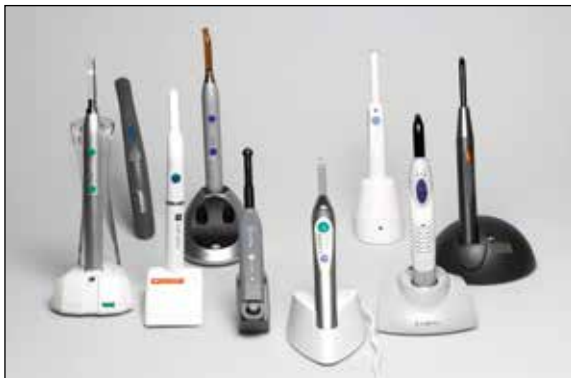The ergonomic Bluephase Style curing light unit produces $1,100 \text{ mW/cm}^2 \pm 10 \%$ and therefore adequate light intensity to cure composite resins efficiently. Due to the technique sensitivity of polymerization, particularly in posterior dentition, manufacturers usually recommend doubling the light-curing time from 10 to 20 seconds per increment. Bluephase Style does not feature any polymerization modes, such as "soft-start" or "low-power". The effectiveness of a "soft-start" mode is questionable for the reduction of shrinkage stress, in particular when a reduction of the curing time is also required (Flemming et al. 2007; Hofmann and Hunecke 2006; Lu et al. 2005; Lu et al. 2004a). From a personal point of view, I consider the influence of the "soft-start" mode to be irrelevant for the clinical result and therefore an unnecessary feature of curing lights.

Like all the other devices from this range of curing lights, Bluephase Style is a 3rd generation polymerization unit featuring the proprietary polywave LED from Ivoclar Vivadent. Devices of the 3rd generation are guaranteed to polymerize all commercially available light-curing dental materials, irrespective of the light initiators they contain. The LEDs emit a halogen-like light spectrum in the violet and blue wavelength range. Devices of the 2nd generation – which are only capable of activating camphorquinone – do not cure all types of materials (Price R BT et al. 2010, 2006, 2005).

LED units of the 3rd generation are characterized by their halogen-like light spectrum. Bluephase Style is suitable for all types of photo-initiators and materials due to the polywave LED.



LED polymerization units of the 2nd generation without the halogen-like light spectrum do not cure all types of materials.



Sculptability

The consistency of bulk filling materials differs quite considerably among the various product systems. While Venus Bulk Fill (Heraeus Kulzer), SDR (Dentsply), Filtek Bulk Fill (3M) and x-tra base (Voco) are flowable, all the other materials including Tetric EvoCeram Bulk Fill are more viscous and therefore firm and sculptable.

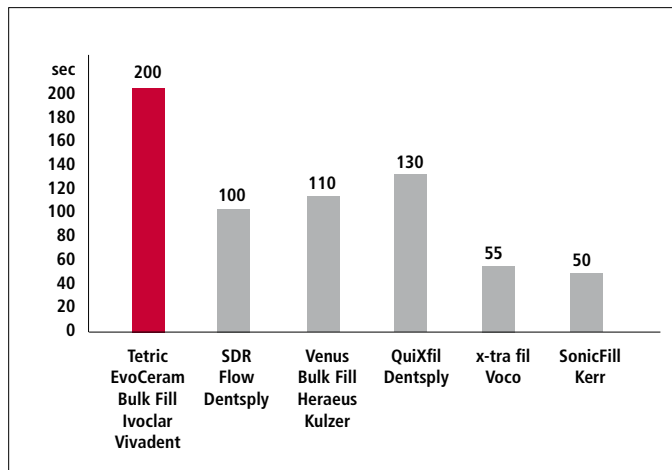
I consider purely flowable materials to be fairly unsuitable for single-layer fillings, as the surface of the restoration cannot be sculpted according to the natural tooth morphology. The flowable consistency may seem convenient for filling large cavities. However, it is more difficult to adapt this type of material without the creation of excess in the reconstruction of occlusal fissures. The recreation of cusps is even more problematic. In most cases, the restorations have to be finished by grinding, which necessitates additional time and may involve the risk of damaging the margins.

Working time under ambient light

The most decisive decision that clinicians need to make in this context is to what extent they should finish the cusp slopes and the fissures before they polymerize the restoration. I myself prefer to recreate the surface morphology as faithfully as possible with deep fissures. The time required for this work is well invested: The need for finishing and polishing at the end is reduced. Moreover, a deep fissure network enlarges the free surface of the cavity. The correspondingly reduced C factor (Feilzer et al. 1987) lowers the setting stress.

Therefore, I really appreciate a material that can be manipulated for an extended period of time under ambient light. In this respect, Tetric EvoCeram Bulk Fill is exemplary among the bulk fillings systems available today.

Long working time according to ISO 4049



Measured according to ISO 4049,
R&D Ivoclar Vivadent, June 2011

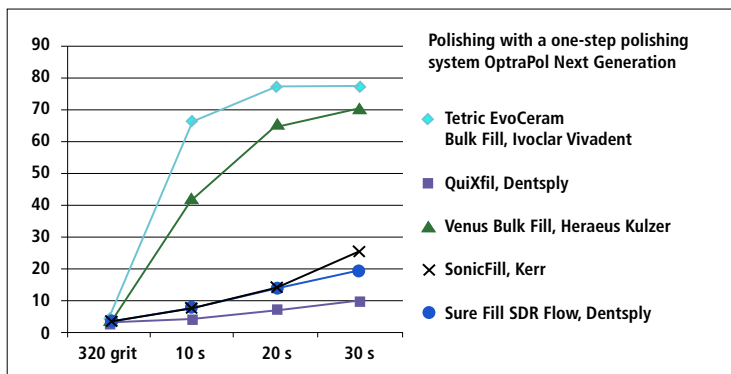
Radiopacity

Dental composites should exhibit a high level of radiopacity to make them distinguishable from the surrounding tooth structure on X-rays. Values of 250 % Al and above are desirable, as they are clearly above those of dental enamel and the standard set by ISO 4049. Studies have shown that some commercial composite resins feature a radiopacity that is below the value of dental enamel or on the level of dentin (Tsuge 2009; Turgut et al. 2003). Therefore, the radiopacity level of 260 % of Tetric EvoCeram Bulk Fill is good. Other bulk filling materials also exhibit values that are rated good to excellent. The radiopacity of Sonic Fill (Kerr) is below the ideal minimum of 250 %.

Polishing properties and esthetic integration


The polishing properties of a material are directly related to the size of the fillers it contains. Among the bulk filling materials, good polishing properties are only offered by Venus Bulk Fill (Heraeus Kulzer) and Tetric EvoCeram Bulk Fill (Heintze et al. 2012).

Gloss measurements, R&D Ivoclar Vivadent, June 2011



The SEM images show the different size fillers used in bulk filling materials. In terms of their appearance, bulk filling materials show certain shortcomings. Even though Tetric EvoCeram Bulk Fill and Venus Bulk Fill (Heraeus Kulzer) feature good polishing properties, they tend to be quite translucent like all bulk filling materials in order to ensure complete cure. The translucency of Tetric EvoCeram Bulk Fill is 15 %. This value is close to that of dental enamel. However, the translucency of Venus Bulk Fill (Heraeus Kulzer) is just under 40 %. Consequently, discoloured areas of the remaining dental hard tissue may shimmer through the restoration and negatively influence the esthetics of the clinical result. Furthermore, the shade range of bulk filling materials is considerably restricted. Darker colours are not available.

Comparison of the fillers of bulk filling materials (Ivoclar Vivadent 2011)



Clinical indications

Tetric EvoCeram Bulk Fill is suitable in all situations where a certain flexibility with regard to the esthetic appearance of fillings is acceptable. As a result, it can be used for placing all types of restorations in the deciduous dentition (with the exception of anterior fillings). Tetric EvoCeram Bulk Fill is clearly preferred over conventional composite resins in these cases. Generally, Tetric EvoCeram Bulk Fill can be placed in one increment, which shortens the procedure and accommodates the often limited compliance of young patients.

In the remaining dentition, Tetric EvoCeram Bulk Fill is primarily indicated for the filling of Class I and Class II cavities. In most cases, the enamel-like translucency of the material does not entail any significant esthetic shortcomings.

Figures 1–15 illustrate two standard cases in which carious lesions were treated. Certain existing stains in the dental hard tissue (e.g. after amalgam fillings) showed to be quite tough. Nevertheless, they were effectively masked by applying an initial thin layer of a relatively opaque flowable composite resin (Tetric EvoFlow A3.5 Dentin).

While the main indication of Tetric EvoCeram Bulk Fill is the placement of fillings in Class I and Class II cavities, larger restorations can be created with the material. However, some esthetic limitations must be accepted in comparison with conventional composite resins, which feature a wide shade range. Nevertheless, the number of increments that need to be placed is almost halved. Most patients, and particularly those that are having an old amalgam filling replaced, are not really concerned about the fact that the bulk filling material does not perfectly match the remaining dental tissue. In general, patients are pleased to have a grey filling replaced by a white one.

From a realistic perspective, a filling is considered to be successfully integrated into its surroundings when it is not visible at a speaking distance. This aim is achieved in every case in which Tetric EvoCeram Bulk Fill is used in the molar region.

The images in Figures 16–54 show how two large single tooth restorations were placed with Tetric EvoCeram Bulk Fill.

Standard case involving carious lesions

Case 1

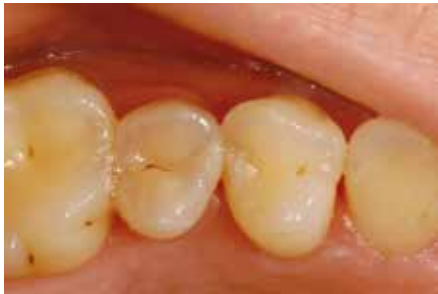

Fig. 1: Pre-operative situation: mesial proximal caries in tooth 15

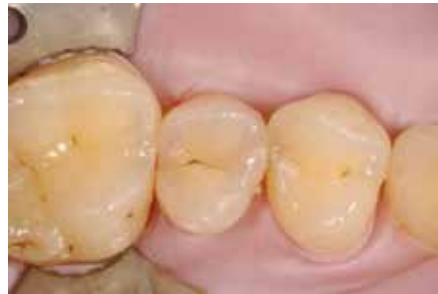

Fig. 2: Rubber dam

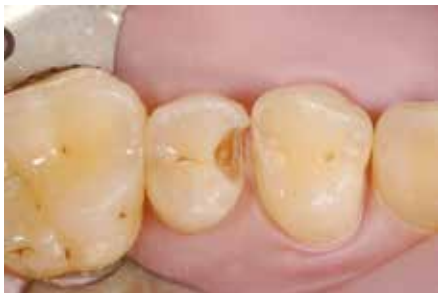

Fig. 3: Prepared tooth with bevelled enamel margins at right angles to the enamel prisms

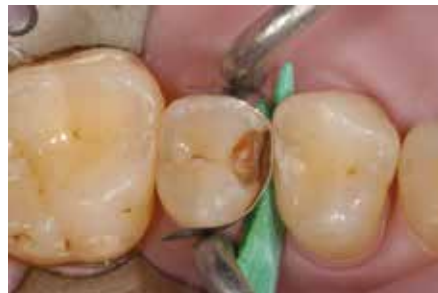

Fig. 4: Application of a sectional matrix

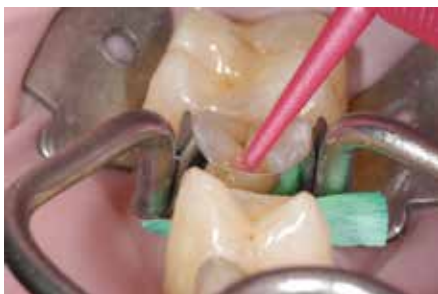

Fig. 5: Application of AdheSE primer

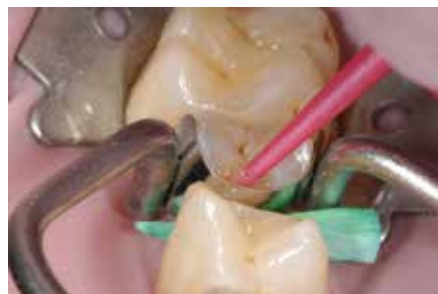

Fig. 6: Application of AdheSE bonding agent

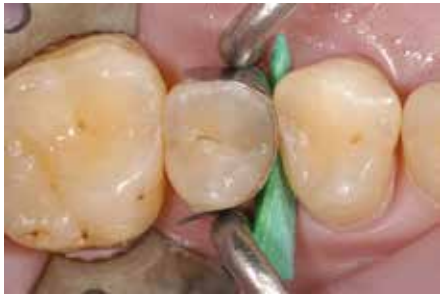

Fig. 7: Filling of the cavity with only one layer of Tetric EvoCeram Bulk Fill

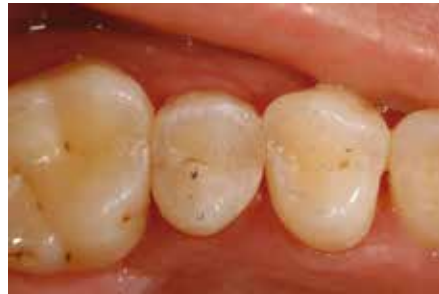

Fig. 8: Examination of the occlusion

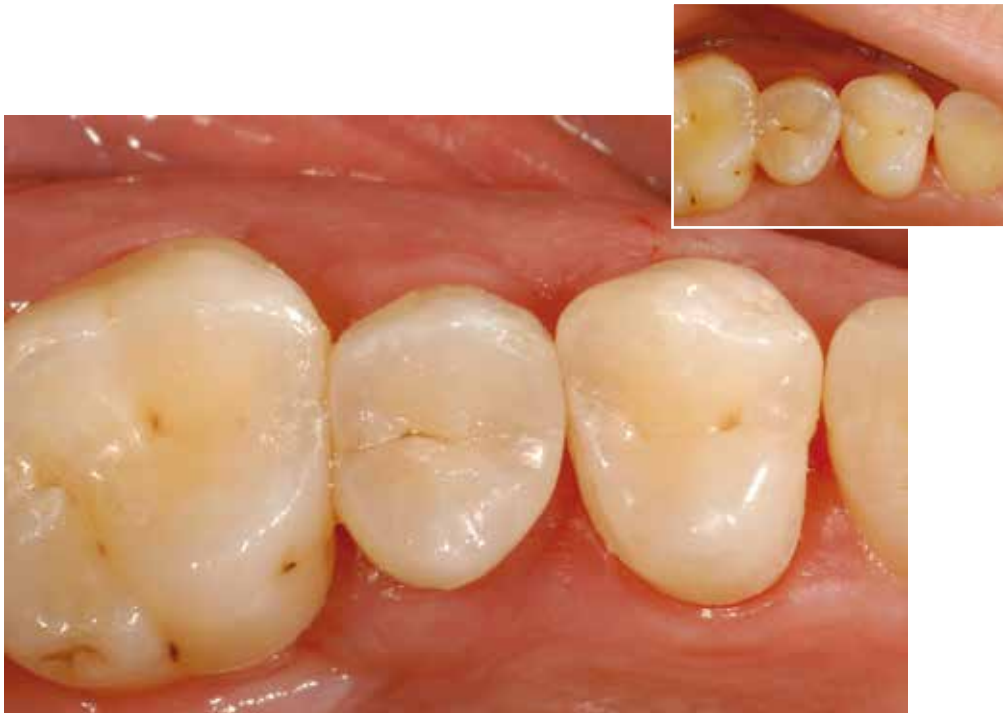

Fig. 9: Completed restoration: Small and medium fillings smoothly blend in with the natural dentition.

Standard case involving carious lesions

Case 2

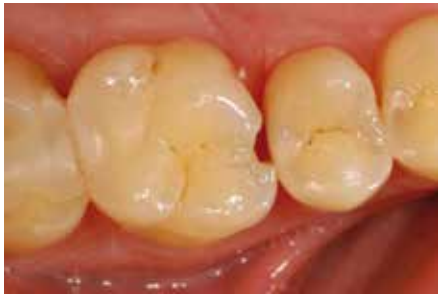

Fig. 10: Pre-operative situation: mesial defect in an upper first molar

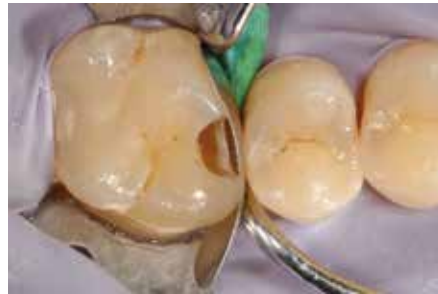

Fig. 11: Situation after establishing a dry working field. Preparation and application of a sectional matrix

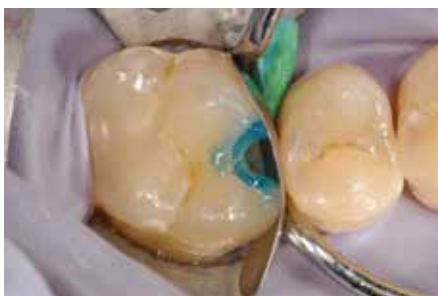

Fig. 12: Selective enamel etching with phosphoric acid for 30 seconds

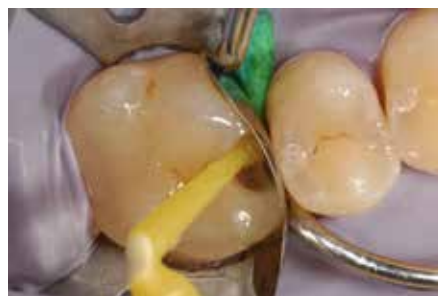

Fig. 13: Application of AdheSE primer and bonding agent

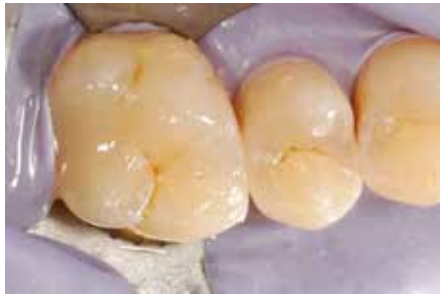

Fig. 14: Filling created with one increment of Tetric EvoCeram Bulk Fill

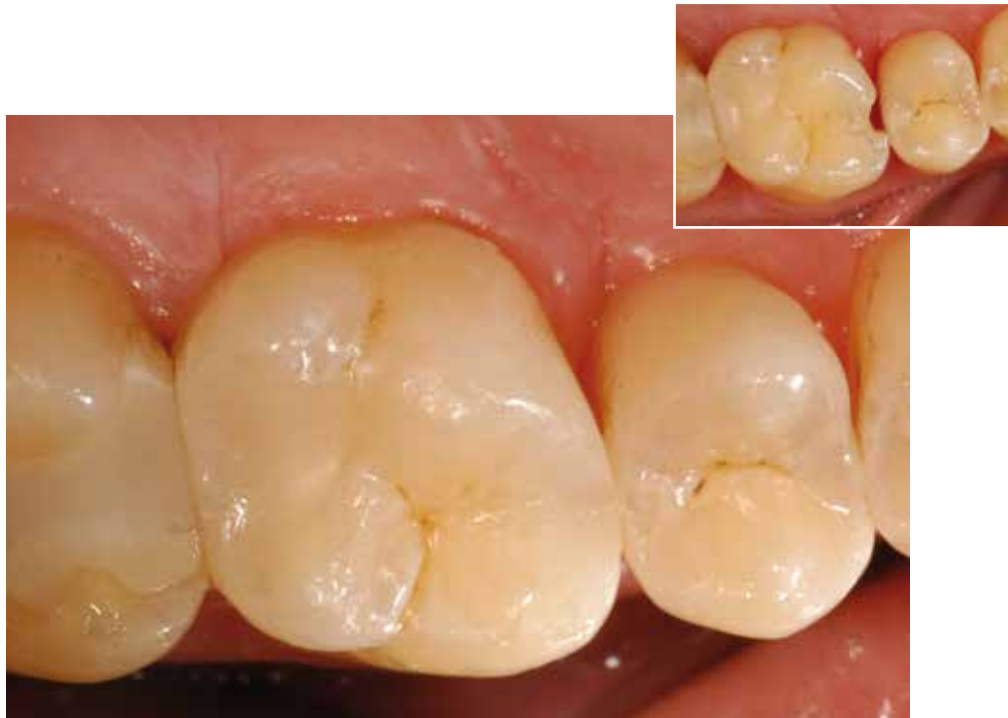

Fig. 15: Completed restoration

Large restorations

Case 1

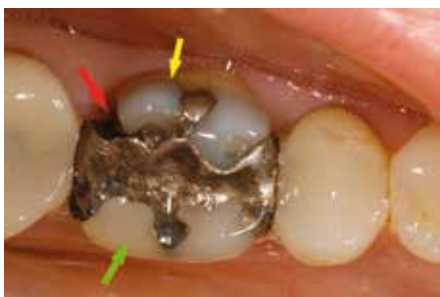

Fig. 16: Pre-operative situation. The patient presented to the dental office with an old amalgam filling in tooth 36. The distal side of the filling was fractured and secondary caries had developed (red arrow). The buccal side of the disto-buccal cusp had a pronounced fracture (yellow arrow). The disto-lingual cusp had been repaired with composite resin. According to the patient, the neighbouring composite resin fillings in tooth 35 and 37 had been placed in the 1990s. These fillings showed marginal discolouration and wear. Nevertheless, they were functionally acceptable.

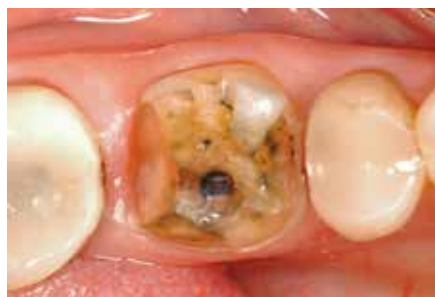

Fig. 17: Situation after tooth preparation. The lingual and disto-buccal cusps broke off during the preparation procedure. The mesio-buccal cusp was reduced by 1.5 mm in order to prevent the preparation margin from being located in the cusp tip. The carious tissue was removed and the distal preparation margin created subgingivally.

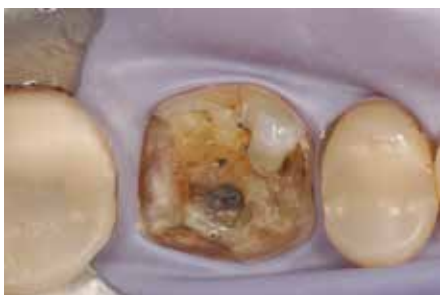

Fig. 18: Even though the use of a rubber dam is not imperative, it nevertheless renders the working conditions much easier.

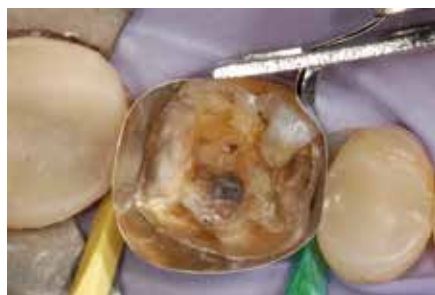

Fig. 19: Situation after the application of a Tofflemire matrix band and wooden wedges. The largest possible wooden wedges were chosen.

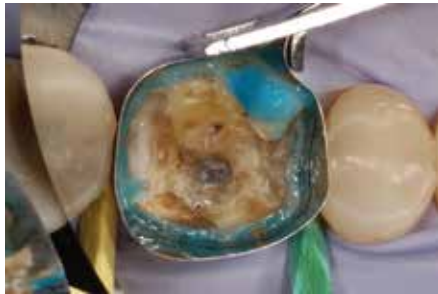

Fig. 20: Selective enamel etching with Total Etch for 30 seconds. For filling medium-to-large size cavities, I prefer to use a selective etching technique together with a 2-bottle self-etch adhesive (AdheSE). (Frankenberger et al. 2008)

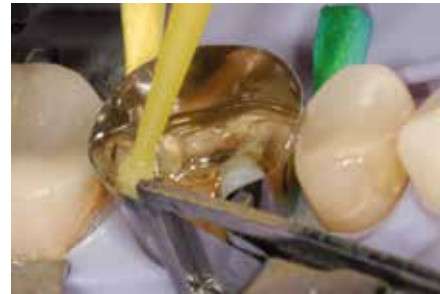

Fig. 21: The AdheSE primer was applied and allowed to react for 30 seconds on the surface before it was dispersed with a strong stream of air. Self-etch adhesives contain a water solvent, which has a low vapour pressure. If the preparation is inadequately dried, water will remain in the hybrid layer and compromise the long-term stability of the bond.

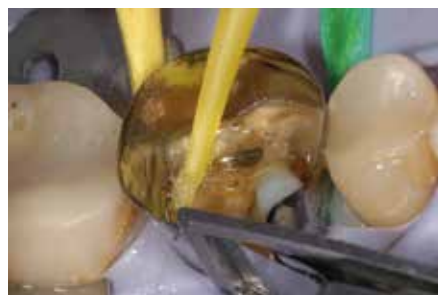

Fig. 22: The AdheSE bonding agent was applied and dispersed with blown air.




Fig. 23: The adhesive was polymerized for 10 seconds with Bluephase Style.

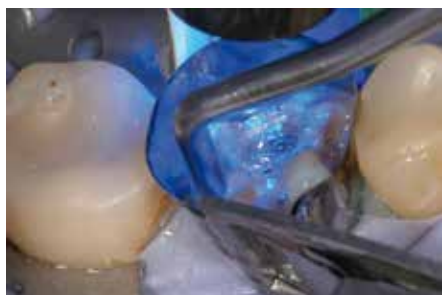

Fig. 24: Even though a Tofflemire matrix is relatively easy to apply when large and subgingival restorations need to be placed, it usually does not allow the tooth contour to be adequately reconstructed. In order to shape the matrix correctly, therefore, a drop of flowable composite resin (Tetric EvoFlow) was applied. A metal condenser was inserted into the unpolymerized composite and the matrix was shaped to reflect the desired contour. While the matrix was held in the desired position with the condenser, the composite was polymerized.

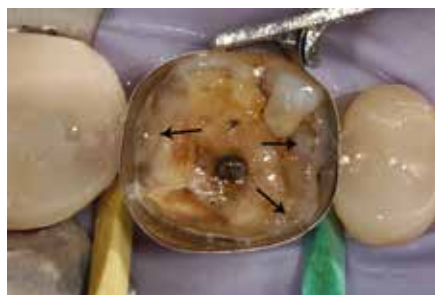

Fig. 25: "Pinpointed": The arrows show the areas in which the matrix was shaped with the flowable composite and a metal condenser.

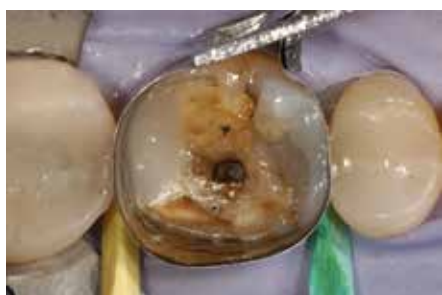

Fig. 26: The first distal and mesial increments of Tetric EvoCeram Bulk Fill were placed together and simultaneously light cured.

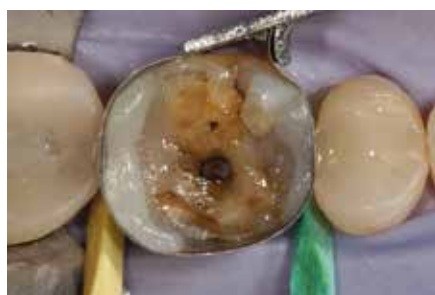

Fig. 27: In a second step, the distal side was completed. A microbrush is significantly more useful than a metal condenser for this purpose.

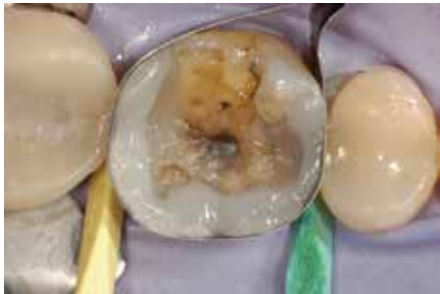

Fig. 28: The third layering step involved the reconstruction of the lingual side.

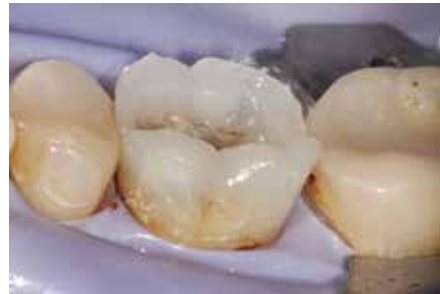

Fig. 29: The buccal side was recreated in the fourth step.

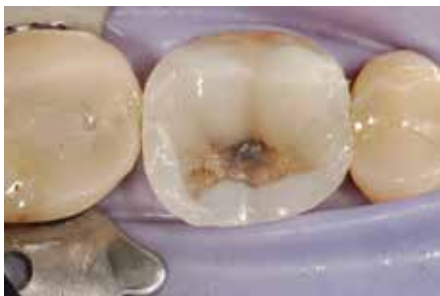

Fig. 30: In the fifth step, the lingual cusp slopes were restored.

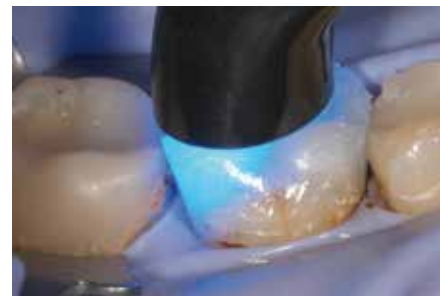


Fig. 31: The light guide must be held as close to the filling surface as possible during polymerization. Due to the 10-mm light guide tip, only one polymerization cycle is needed.

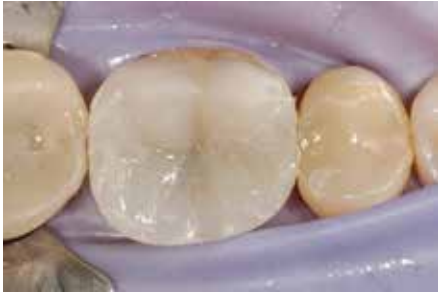

Fig. 32: The sixth and last build-up step: Fabrication of the buccal cusp slopes

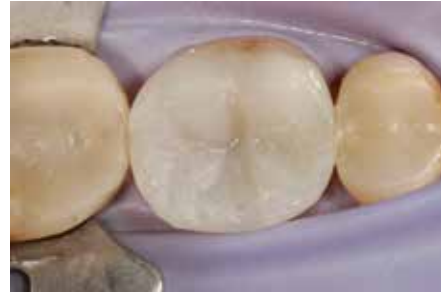

Fig. 33: Finishing consisted of removing excess composite on the buccal and lingual sides with flexible discs.

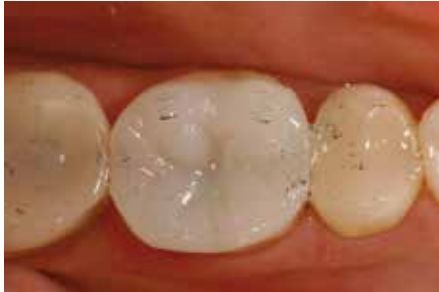

Fig. 34: Before the occlusal areas of the restoration were finished, the occlusion was checked.

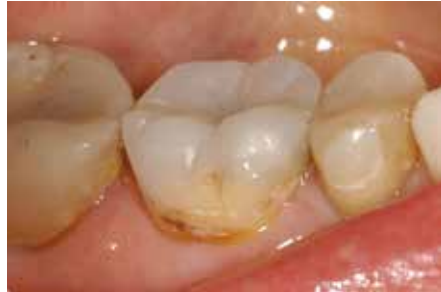

Fig. 35: Buccal view of the completed restoration

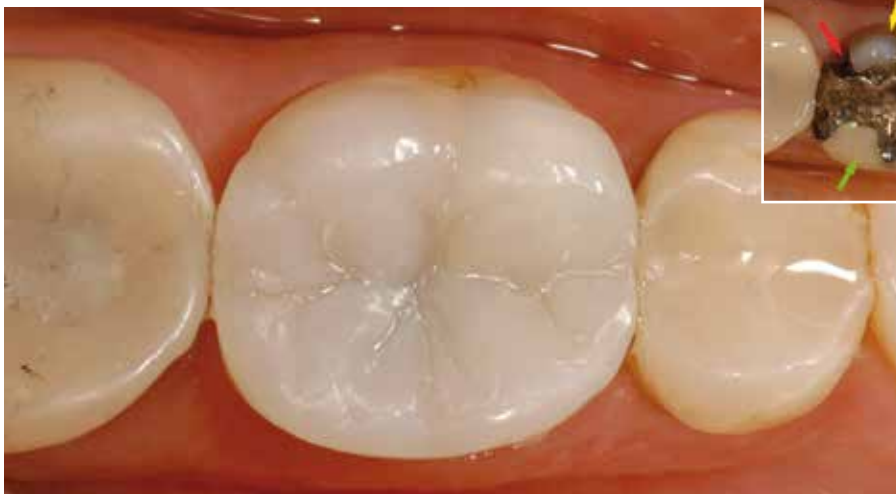

Fig. 36: Occlusal view. The material smoothly blends in with the colour of the natural dentition of shade A3; any darker would not be ideal. Nevertheless, the clinical relevance of this shortcoming in the posterior region is minimal.

Large restorations

Case 2

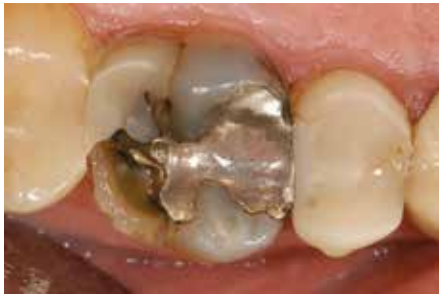

Fig. 37: Pre-operative view. A fractured upper first molar showing caries and old restorations

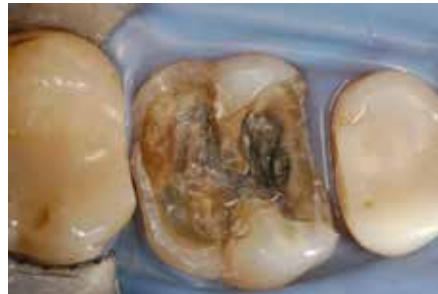

Fig. 38: Situation following the application of a rubber dam and the removal of caries and the old fillings

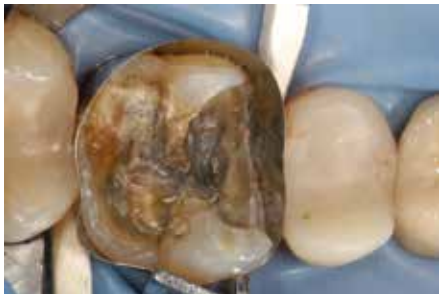

Fig. 39: Application of a matrix band

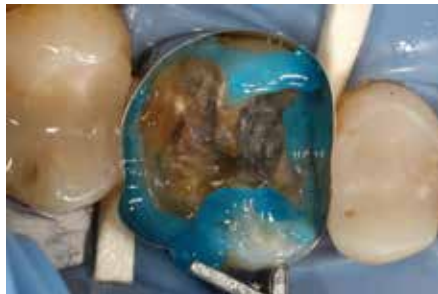

Fig. 40: Selective enamel etching for 30 seconds

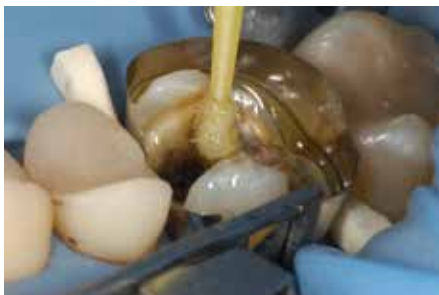

Fig. 41: Adhesive bonding with a 2-bottle self-etch adhesive (AdheSE)

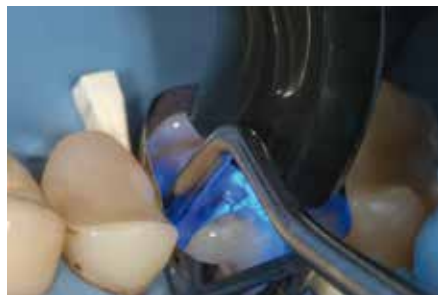

Fig. 42: "Pinpointing" of the matrix: A flowable composite resin (Tetric EvoFlow A3.5 Dentin) was displaced with a metal condenser to shape the matrix as desired.

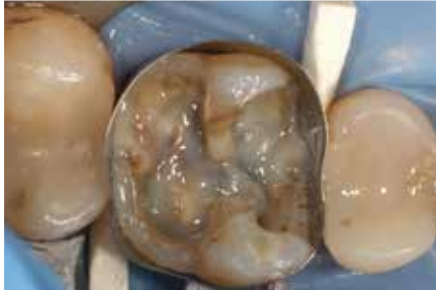

Fig. 43: Situation after the matrix was shaped. The relatively opaque Tetric EvoFlow A3.5 Dentin helps to mask the stained dentin tissue.

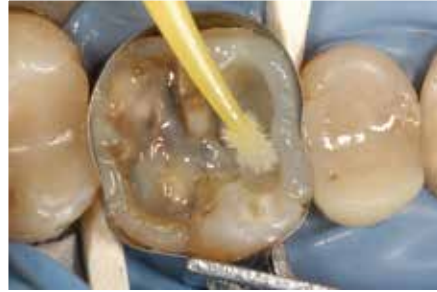

Fig. 44: The material was placed and adapted with a microbrush. As a microbrush was used instead of a metal condenser the material remained on the tooth surface and did not stick to the instrument.

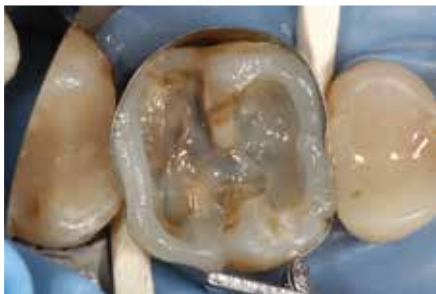

Fig. 45: In a first step, the proximal sides were built up. The material was exceptionally easy to contour.

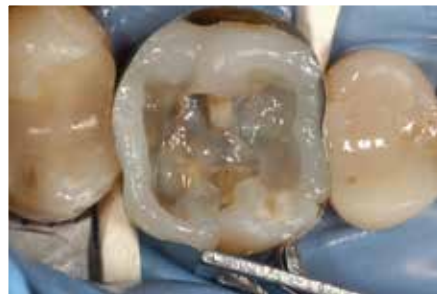

Fig. 46: The palatal part of the side was completed.

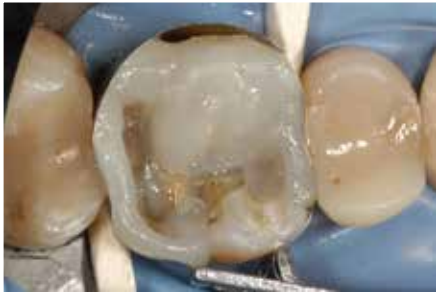

Fig. 47: Build-up of the mesio-palatal cusp

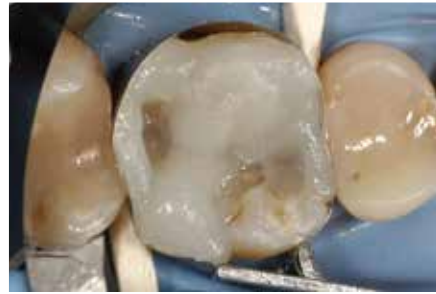

Fig. 48: Build-up of the disto-buccal cusp

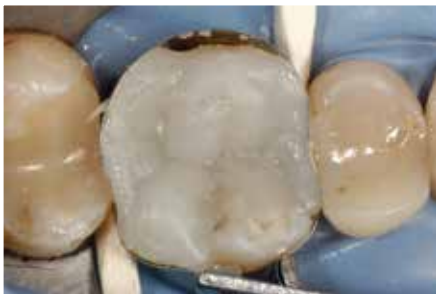

Fig. 49: Creation of the remaining cusp slopes

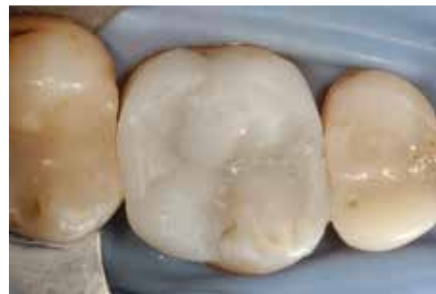

Fig. 50: Removal of excess material

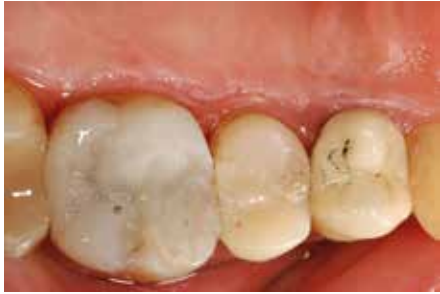

Fig. 51: Establishment of proper occlusion

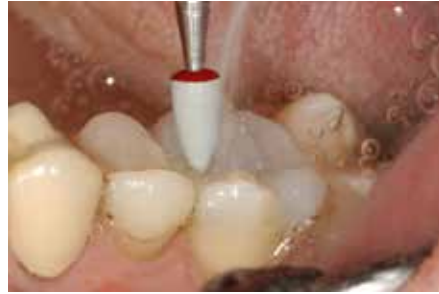

Fig. 52: Polishing of the surface with OptraPol Next Generation

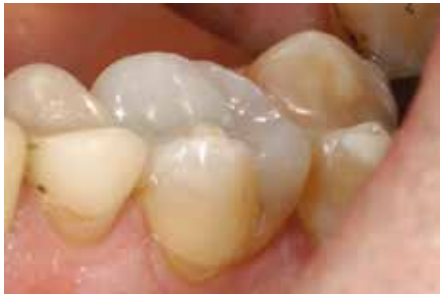

Fig. 53: Mesio-buccal view of the completed restoration. The excellent polishing properties of Tetric Evo-Ceram Bulk Fill are clearly visible.

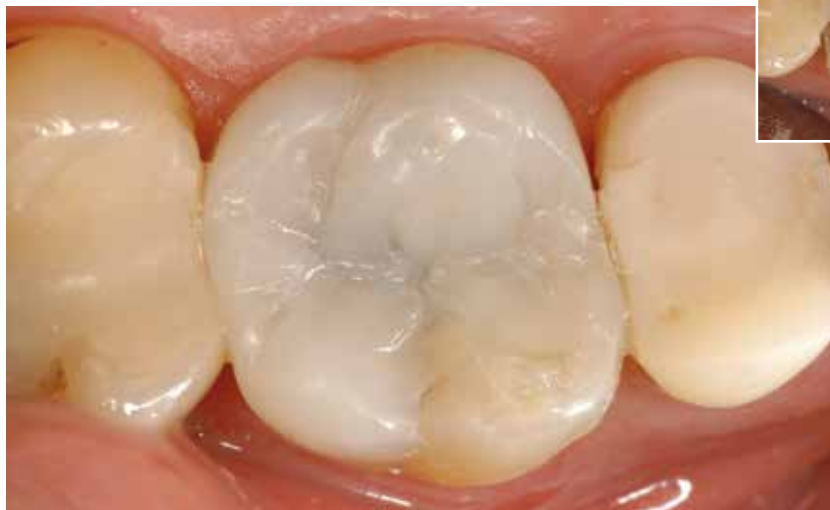

Fig. 54: Occlusal view

Assessment

In my opinion Tetric EvoCeram Bulk Fill is an exceptional bulk filling material. I am unaware of any disadvantages compared with conventional composite resins, with the exception of the restricted shade range. However, I do know that it offers excellent handling properties and the possibility of considerably streamlining build-up procedures.

The esthetic integration of bulk fillings in Class I and Class II cavities is thoroughly acceptable, even when cusps have to be replaced. But beware you may become addicted to using this material: Once you have tried it, you may not want to use conventional composite resins any longer. This material has established a special place in my practice.



A handwritten signature in black ink, appearing to read 'M. Lenhard'.

Dr Markus Lenhard
Vordergasse 30
8213 Neunkirch
Switzerland
markus.lenhard@bluewin.ch

Literature references

Barghi, N, Berry T, Hatton C (1994). Evaluating intensity output of curing lights in private dental offices. *J Am Dent Assoc* 125(7): 992-996.

Barghi N et al. (2007). Revisiting the Intensity Output of Curing Lights in Private Dental Offices. *Compendium*28(7): 380-385.

Bogacki RE, Hunt RJ, del Aguila M, Smith WR (2002). Survival analysis of posterior restorations using an insurance claims database. *Oper Dent* 27: 488-492.

Deliperi S, Bardwell DN (2006). Clinical evaluation of direct cuspal coverage with posterior composite resin restorations. *J Esthet Restor Dent*. 18(5): 256-65.

El-Mowafy O et al. (2005). Intensity of quartz-tungsten-halogen light-curing units used in private practise in Toronto. *J Am Dent Assoc*136: 766-773.

Ernst CP, Busemann I, Kern T, Willershausen B (2006). Feldtest zur Lichtemissionsleistung von Polymerisationsgeräten in zahnärztlichen Praxen. *Dtsch Zahnärztl Z* 61(9): 466-471.

Feilzer AJ, De Gee AJ, Davidson CL (1987). Setting stress in composite resin in relation to configuration of the restoration. *J Dent Res* 66: 1636-1639.

Felix CA, Price RB (2003). The effect of distance from light source on light intensity from curing lights. *J Adhes Dent* 5(4): 283-91.

Fleming GJ, Cara RR, Palin WM, Burke FJ (2007). Cuspal movement and microleakage in premolar teeth restored with resin-based filling materials cured using a ‚soft-start‘ polymerisation protocol. *Dent Mater* 23(5): 637-43.

Frankenberger R, Lohbauer U, Roggendorf MJ, Naumann M, Taschner M (2008). Selective enamel etching reconsidered: better than etch-and- rinse and self-etch? *J Adhes Dent* 10(5): 399-344.

Heintze S, Forjanic M, Zellweger G, Antonson S (2012). Polishability and wear behaviour of resin composite bulk fill materials. *AADR abstract no.* 156143.

Hofmann N, Hunecke A (2006). Influence of curing methods and matrix type on the marginal seal of class II resin-based composite restorations in vitro. *Oper Dent* 31(1): 97–105.

Illie N, Kunzelmann KH, Hickel R (2005). Werkstoffkundliche Untersuchungen zu Kompositen. *Dtsch Zahnärztl Z* 60(6): 321-334.

Kujis RH, Fennis WM, Kreulen CM, Roeters FJ, Creugers NH, Burgersdijk RC (2006). A randomized clinical trial of cusp-replacing resin composite restorations: efficiency and short-term effectiveness. *Int J Prosthodont* 19(4): 349-354.

Lange RT, Pfeiffer P (2009). Clinical evaluation of ceramic inlays compared to composite restorations. *Oper Dent* 34(3): 263-72.

Lu H, Stansbury JW, Bowman CN (2004 a). Towards the elucidation of shrinkage stress development and relaxation in dental composites. *Dent Mat* 20: 979-986.

Lu H, Stansbury JW, Bowman CN. (2005). Impact of curing protocol on conversion and shrinkage stress. *J Dent Res* 84(9): 822-6.

Matošević D, Pandurić V, Janković B, Knežević A, Klarić E, Tarle Z (2011). Light Intensity of Curing Units in Dental Offices in Zagreb, Croatia (Intenzitet svjetlosti polimerizacijskih uređaja u ordinacijama dentalne medicine u Zagrebu, Hrvatska). *Acta Stomatol Croat* 45(1): 31-40.

Mahn E. (2010). Lichtintensität auf dem Prüfstand – Messen nach allen Regeln der Kunst. *DZW* 22: 18-19.

Opdam NJ, Bronkhorst EM, Loomans BA, Huysmans MC (2010). 12-year survival of composite vs. amalgam restorations. *J Dent Res* 89(10): 1063-1067.

Opdam NJ, Roeters JJ, Loomans BA, Bronkhorst EM (2008). Seven-year clinical evaluation of painful cracked teeth restored with a direct composite restoration. *J Endod* 34(7): 808–811.

Price RB, Dérand T, Sedarous M, Andreou P, Loney RW (2000). Effect of distance on the power density from two light guides. *J Esthet Dent* 12(6): 320-327.

Price R BT, Fahey J, Felix C (2010). Knoop hardness of five different composites cured with single-peak and polywave LED curing lights. *Quintessence Int* 41: e181-e191.

Price R BT (2005). Evaluation of a dual peak third generation LED curing light. Department of Dental Clinical Sciences, Dalhousie University, Halifax, Nova Scotia, Canada. *Compend Contin Educ Dent* (26): 331-2, 334, 336-8 passim; quiz 348.

Price R BT (2006). Third generation vs a second-generation LED curing light: effect on Knoop microhardness. Department of Dental Clinical Sciences, Dalhousie University, Halifax, Canada. *Compend Contin Educ Dent* (27): 490-6; quiz 497, 518.

Santos GC et al.(2005). Intensity of Quartz-Tungsten-Halogen Light Polymerization Units Used in Dental Offices in Brazil. *Int J Prosthodont* 18:434-435.

Tsuge T (2009). Radiopacity of conventional, resin-modified glass ionomer and resin-based luting materials. *J Oral Sci* 51(2): 223-230.

Turgut MD, Attar N, Onen A (2003). Radiopacity of direct esthetic restorative materials. *Oper Dent* 28 (5): 508-514.

